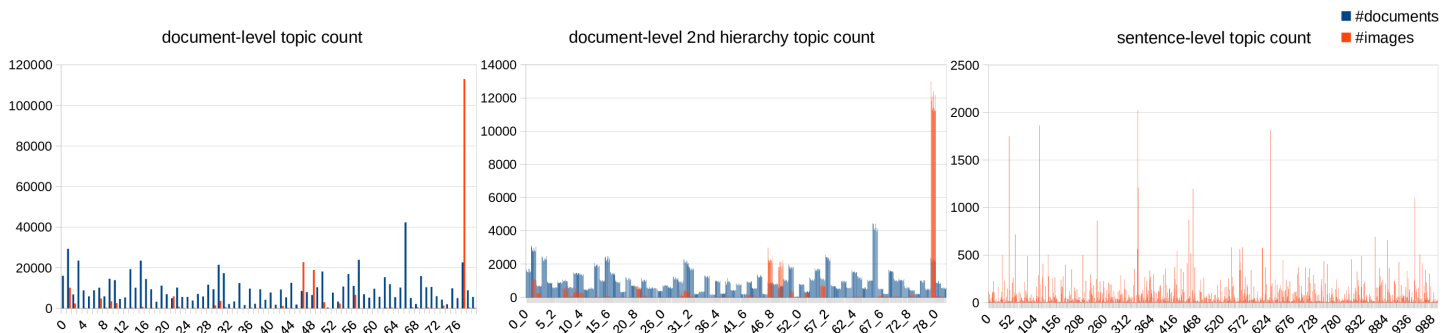


# Interleaved Text/Image Deep Mining on a Large-Scale Radiology Database

Hoo-Chang Shin, Le Lu, Lauren Kim, Ari Seff, Jianhua Yao, Ronald M. Summers  
Supplementary Material, CVPR 2015

## 1. Distribution of documents and images for LDA topics.

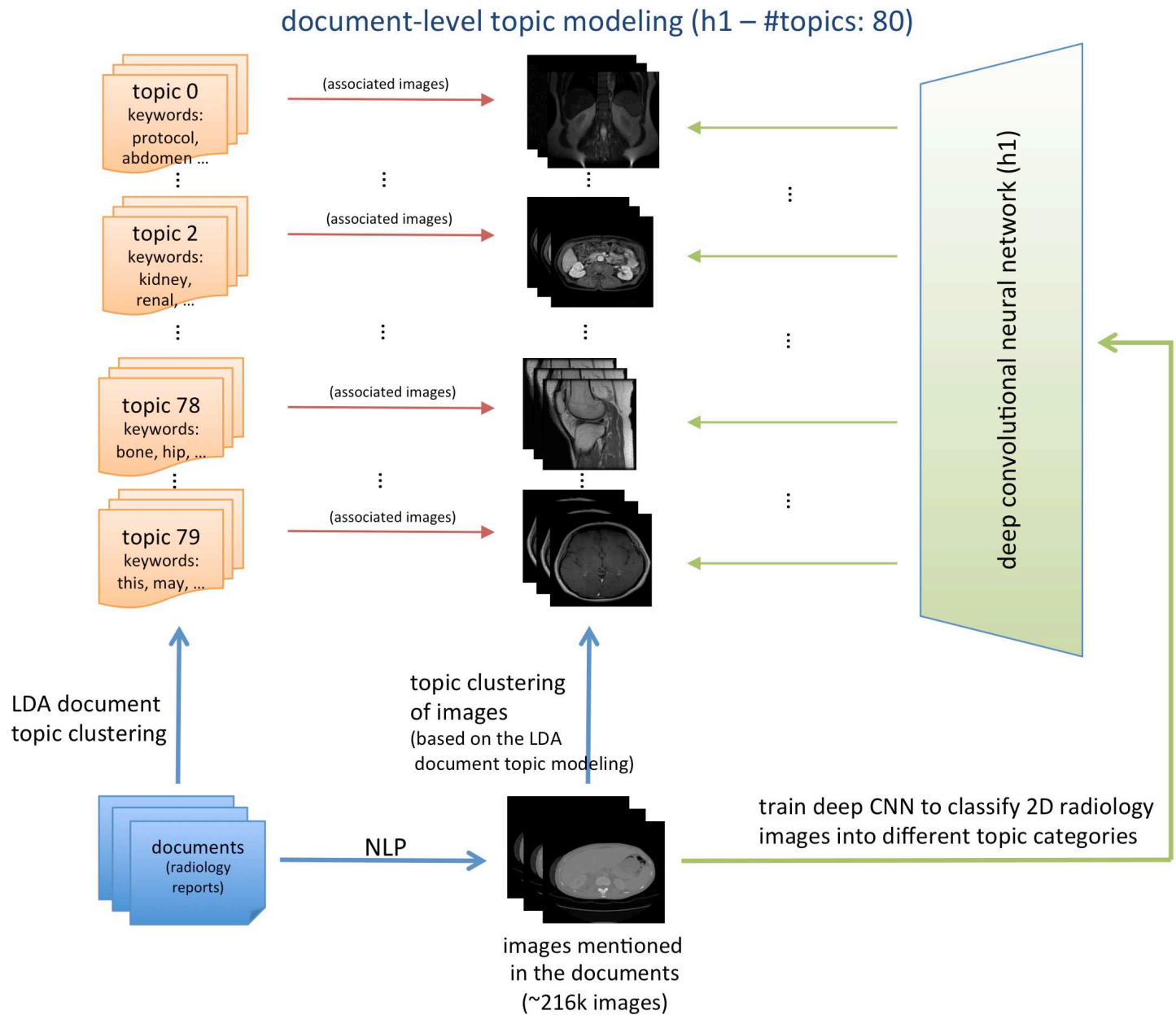


2. Word-to-vector models trained on a collection of biomedical research articles (from OpenI (<http://openi.nlm.nih.gov/>) and radiology reports, and radiology reports only. Search words (with quotes) and their closest words in vector-space cosine similarity (higher the better) are listed in a descending order.

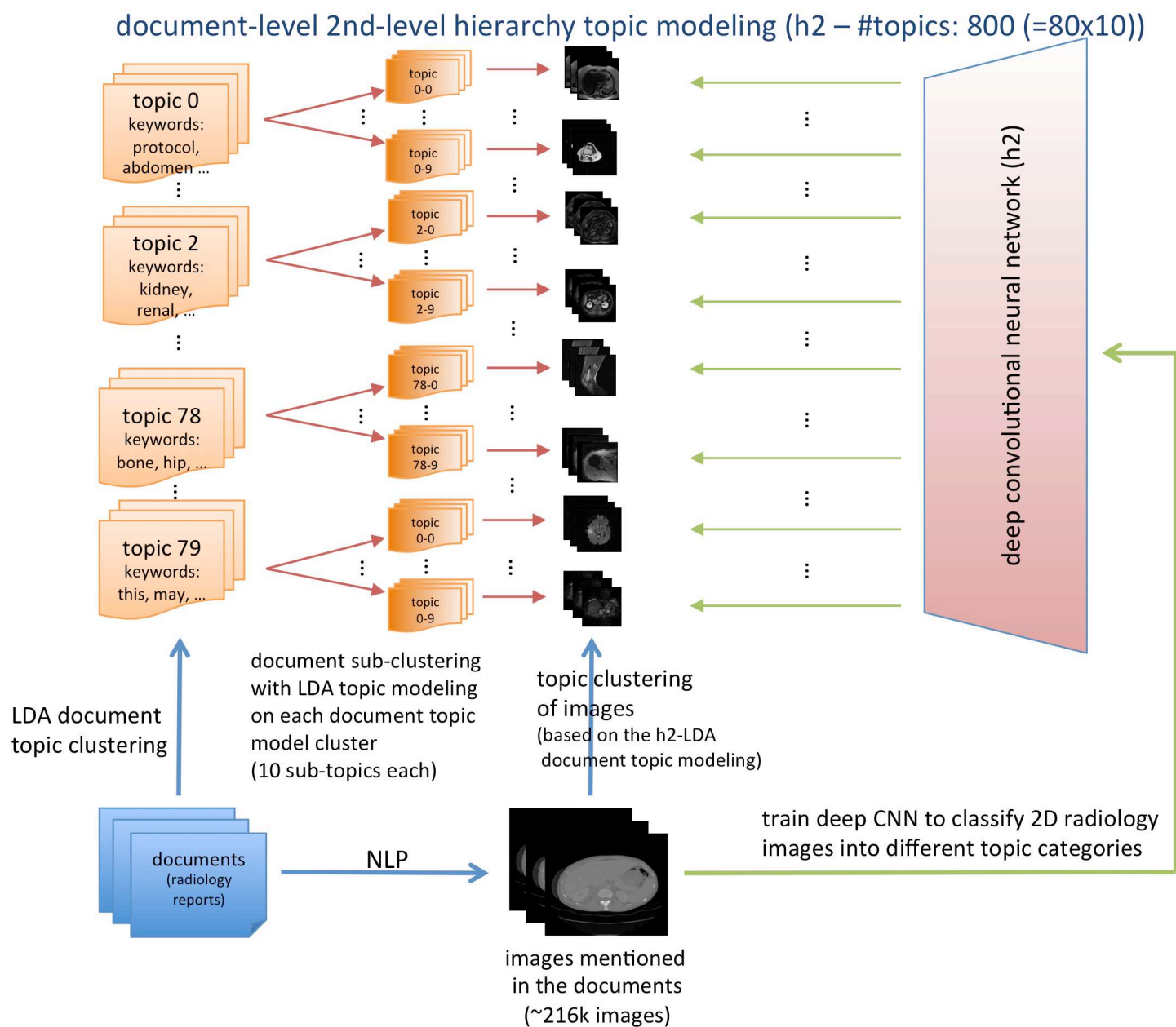
~1.2 billion words with OpenI	~1.2 billion words with OpenI	~1.2 billion words with OpenI	~1.2 billion words with OpenI
<b>"cyst"</b>	<b>"heart"</b>	<b>"brain"</b>	<b>"liver"</b>
cysts 0.799191	cardiac 0.672690	hemisphere 0.684149	hepatic 0.764163
hydatid 0.734686	respiratory 0.644453	hemispheric 0.668626	spleen 0.683242
cystic 0.701855	beat 0.642630	cerebellum 0.663902	cirrhotic 0.664428
unilocular 0.654273	pressure 0.558879	whole 0.661564	cirrhosis 0.664262
tailgut 0.639764	murmur 0.551323	regions 0.647632	hcc 0.656473
nonparasitic 0.621647	systolic 0.548490	mri 0.646674	portal 0.610437
epidermoid 0.604492	pericardial 0.538957	structural 0.638171	hepatocellular 0.603930
lipoma 0.588372	dobutamine 0.537429	neuroanatomical 0.636563	parenchyma 0.597169
cheesy 0.586947	intracardiac 0.533799	crinoid 0.626951	splenic 0.579957
multiloculated 0.584199	great 0.532735	in 0.626707	hepatomegaly 0.573687
pearly 0.583126	rate 0.531352	parasagittal 0.618392	tumor 0.571135
multilocular 0.582670	beats 0.524729	illustration 0.610440	abdomen 0.559092
lesion 0.579009	atrial 0.524052	striatal 0.609282	hepatectomy 0.556156
tgdc 0.578533	tachycardia 0.521093	brains 0.607442	bcll 0.546798
multiseptate 0.575851	minute 0.520249	behavioral 0.606803	subcapsular 0.542745
~1 billion words reports only	~1 billion words reports only	~1 billion words reports only	~1 billion words reports only
<b>"cyst"</b>	<b>"heart"</b>	<b>"brain"</b>	<b>"liver"</b>
cysts 0.768382	lungs 0.526600	t1 0.615066	spleen 0.759884
septated 0.586067	mediastinum 0.517008	mri 0.595027	gallbladder 0.648075
polyp 0.583761	consolidating 0.486605	sagittal 0.580841	hepatomegaly 0.642022
simple 0.534717	pa 0.449816	flair 0.565445	gallstones 0.611837
septation 0.500951	chest 0.433362	t2 0.555053	pancreas 0.608356
parapelvic 0.500877	infiltrates 0.428404	axial 0.554040	gallstone 0.606063
incidental 0.500760	hyperinflated 0.413326	spgr 0.520954	steatosis 0.601081
small 0.487211	cardiomegaly 0.410785	weighted 0.502047	dome 0.594812
cystic 0.477632	hyperlucent 0.400836	technique 0.487768	portal 0.570008
pole 0.471933	pectus 0.396142	astrocytoma 0.480527	ascites 0.551869
multiseptated 0.469851	great 0.395712	gbm 0.476956	hepatosplenomegaly 0.540501
polyps 0.464380	ectatic 0.394560	gradient 0.476593	hepatic 0.537453
exophytic 0.459088	shifted 0.389205	oligodendroglioma 0.465892	cirrhosis 0.530389
hyperdense 0.457558	ray 0.389091	postcontrast 0.463686	fatty 0.522134
mucous 0.448427	infiltrate 0.387224	3d 0.458123	kidneys 0.515252

### 3. Systematic Diagrams

(1) Document-level topic modeling, training CNNs to learn to classify images into the topics

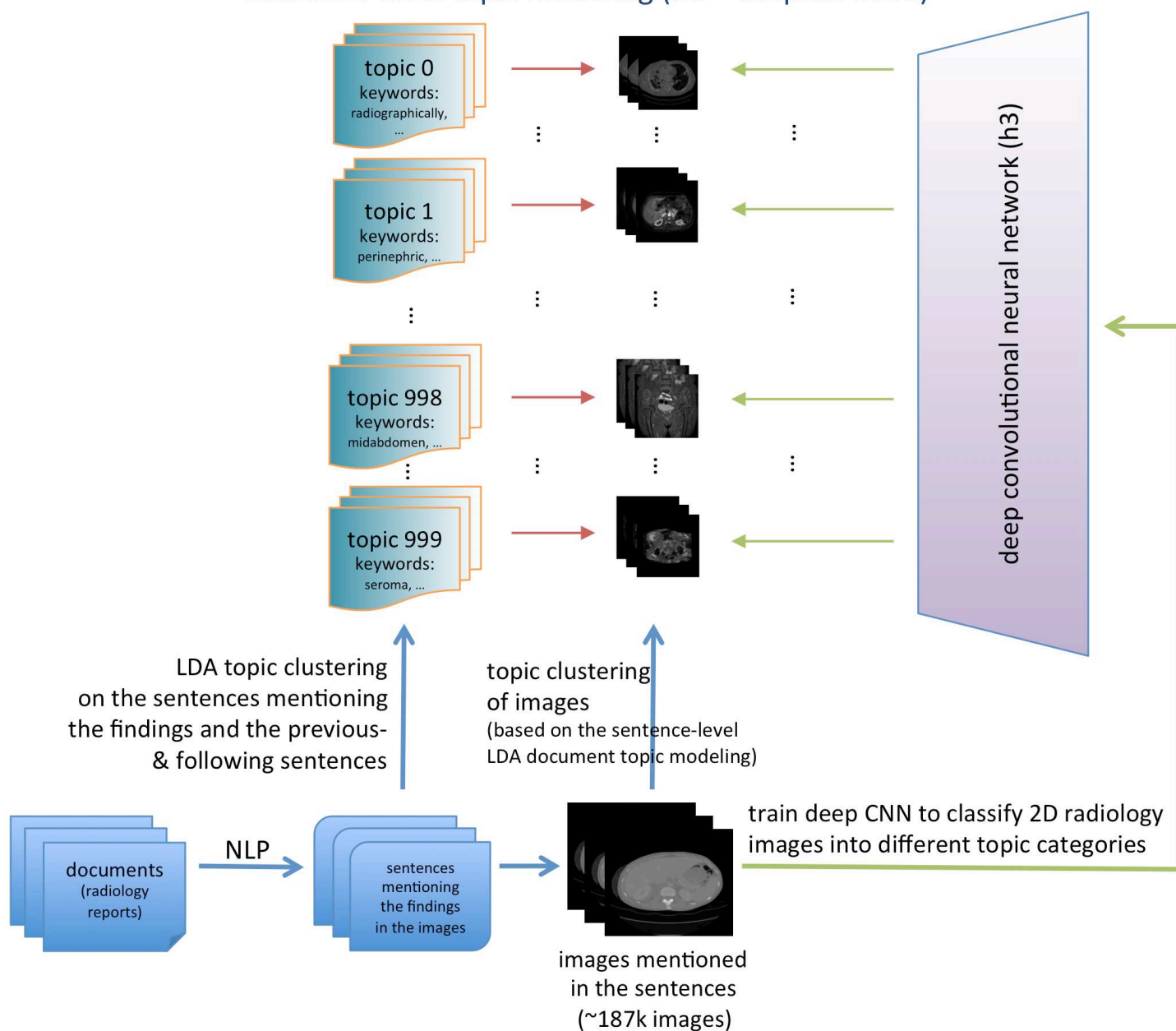


(2) Document-level 2nd-hierarchy topic modeling, training CNNs to learn to classify images into the topics

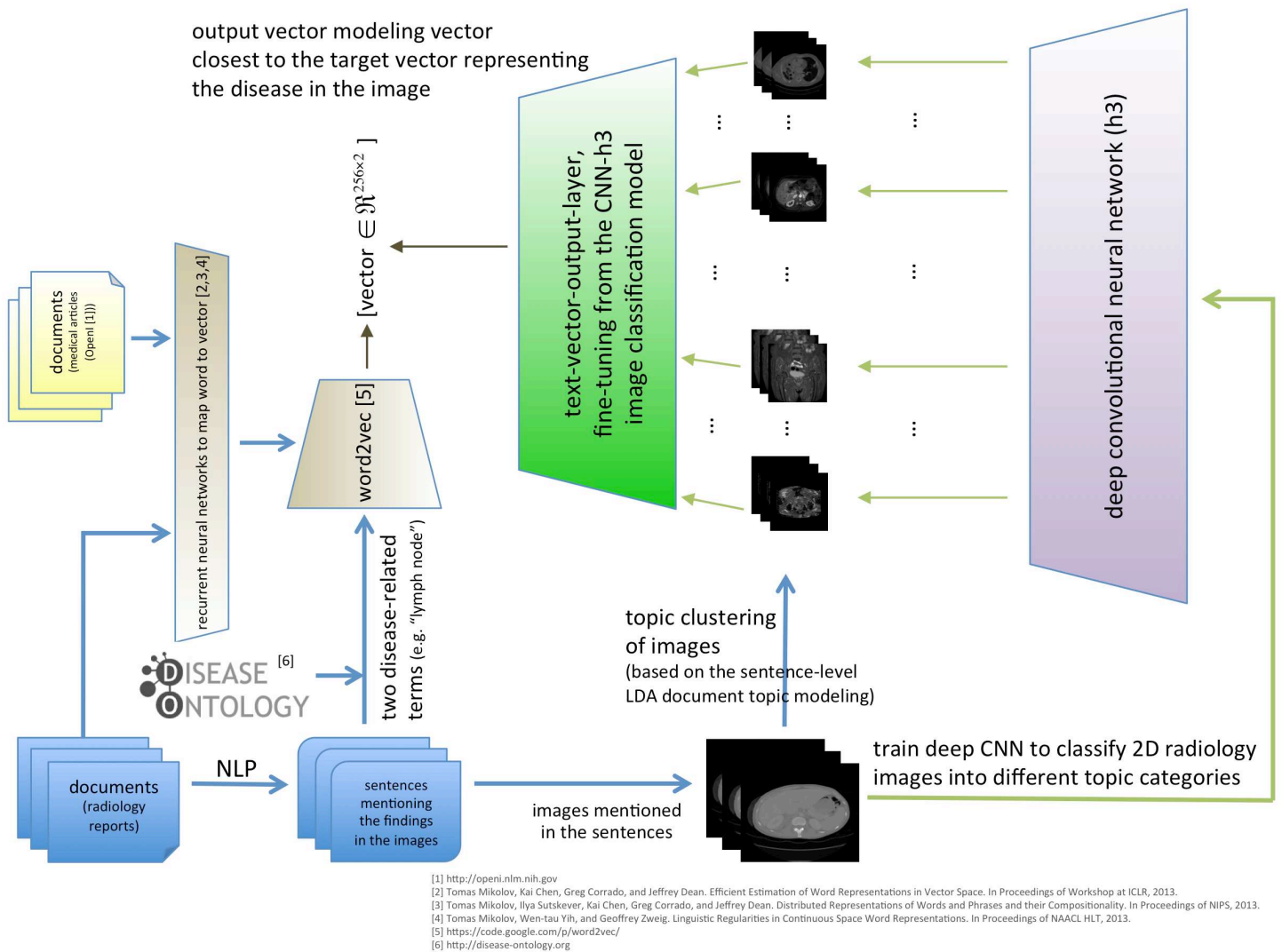


(3) Sentence-level topic modeling, training CNNs to learn to classify images into the topics

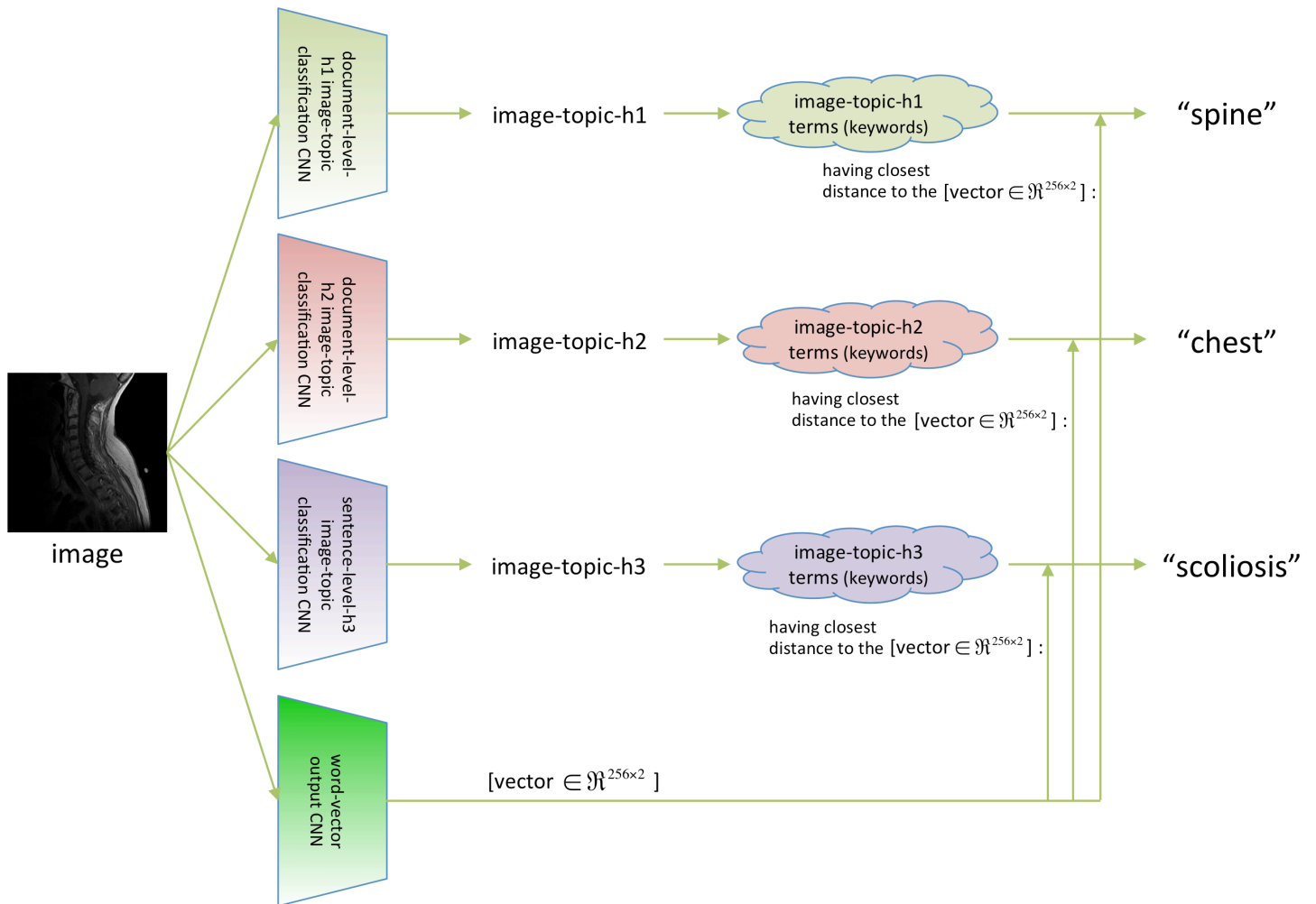
sentence-level topic modeling (h3 – #topics: 1000)



(4) “word2vector” deep model, training a CNN to model image to word vectors

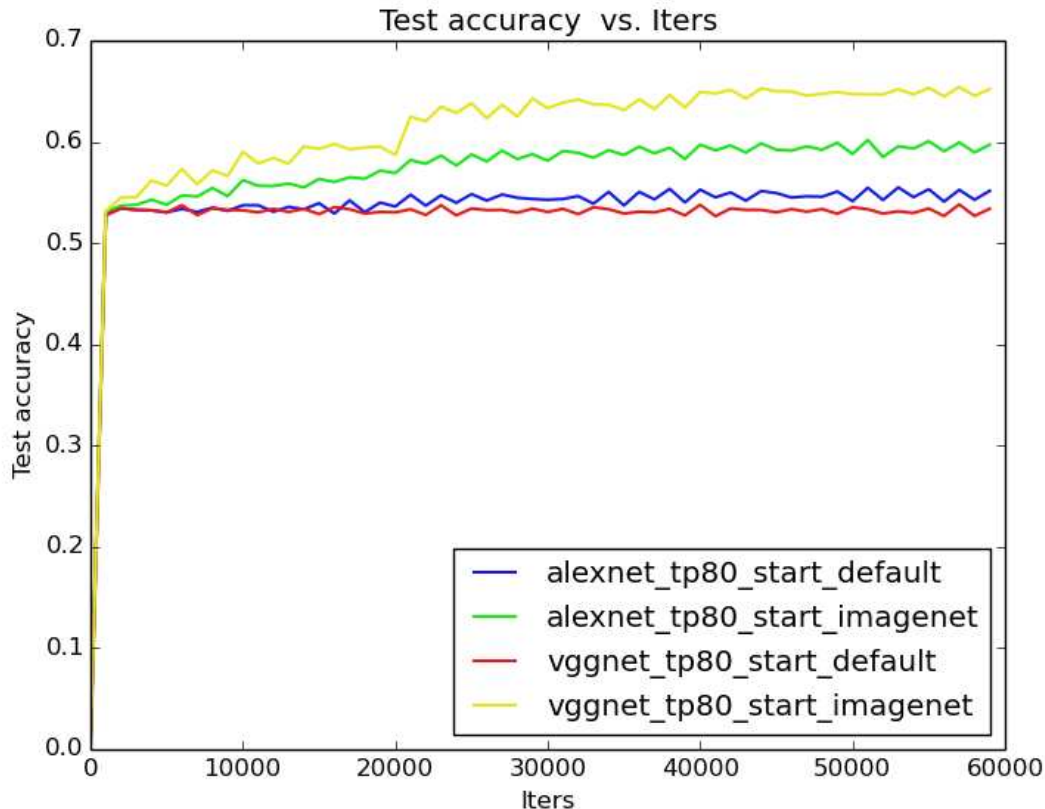


(5) Term predicting flow-chart: given a new image, (i) classify the image into different levels of topic categories, (ii) map the image as a word-vector, (iii) find a word from each topic terms (keywords) having closest distance to the word-vector output (iv) to describe the image



#### 4. Benefits of using ImageNet dataset as pre-training for this task with medical images and improvements of fine-tuning from CNN neural networks of similar tasks (e.g., from document-level-h1 CNN model to document-level-h2 CNN model)

(2.1) document-level-h1 image-topic classification:



Above are the plots of the test accuracy progression along the training iterations (batch size of 50 images), where the weights of CNNs are:

- randomly initialized, AlexNet 8-layers (alexnet\_tp80\_start\_default)
- randomly initialized, VGG-Net 19-layers (vggnet\_tp80\_start\_default)
- fine-tuned from the ImageNet dataset, AlexNet 8-layers (alexnet\_tp80\_start\_imagenet)
- fine-tuned from the ImageNet dataset, VGG-Net 19-layers (vggnet\_tp80\_start\_imagenet)

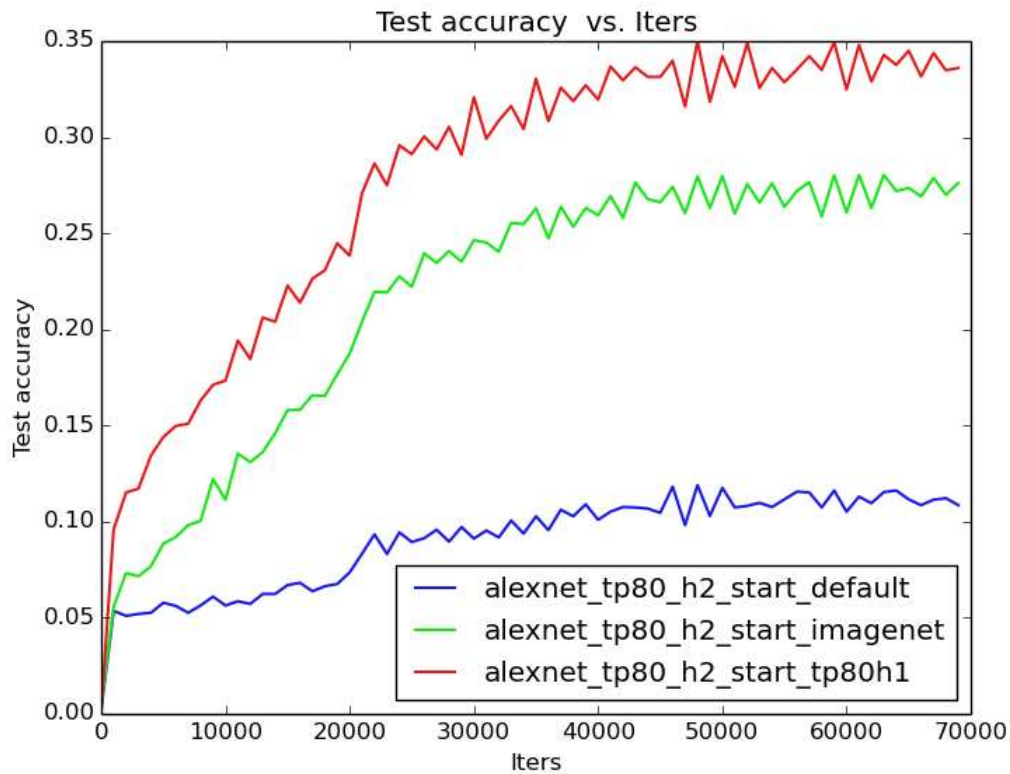
These plots show that

- (i) It is clearly beneficial to fine-tune from the ImageNet dataset even for medical images dataset (from RGB to CT/MRI), especially when the dataset is unbalanced.
- (ii) A more complex, deeper CNN model (VGG-Net) performs better than already a good benchmark (AlexNet), but **only** when starting from a good initialization (i.e., pre-training via ImageNet models)
- (iii) CNN testing accuracy increases from ~0% to 50+% quickly in about 1600 iterations due to the unbalanced data amount distribution among classes in document-level-h1. The distribution in document-level-h2 is more balanced.

Note that this may be the largest scale experiment on deep CNN's cross-modality image generality study.



## (2.2) document-level-h2 image-topic classification



Above are the plots of the test accuracy progression along the training iterations (batch size of 50 images), where the weights of CNNs (variations of AlexNet 8-layers) are:

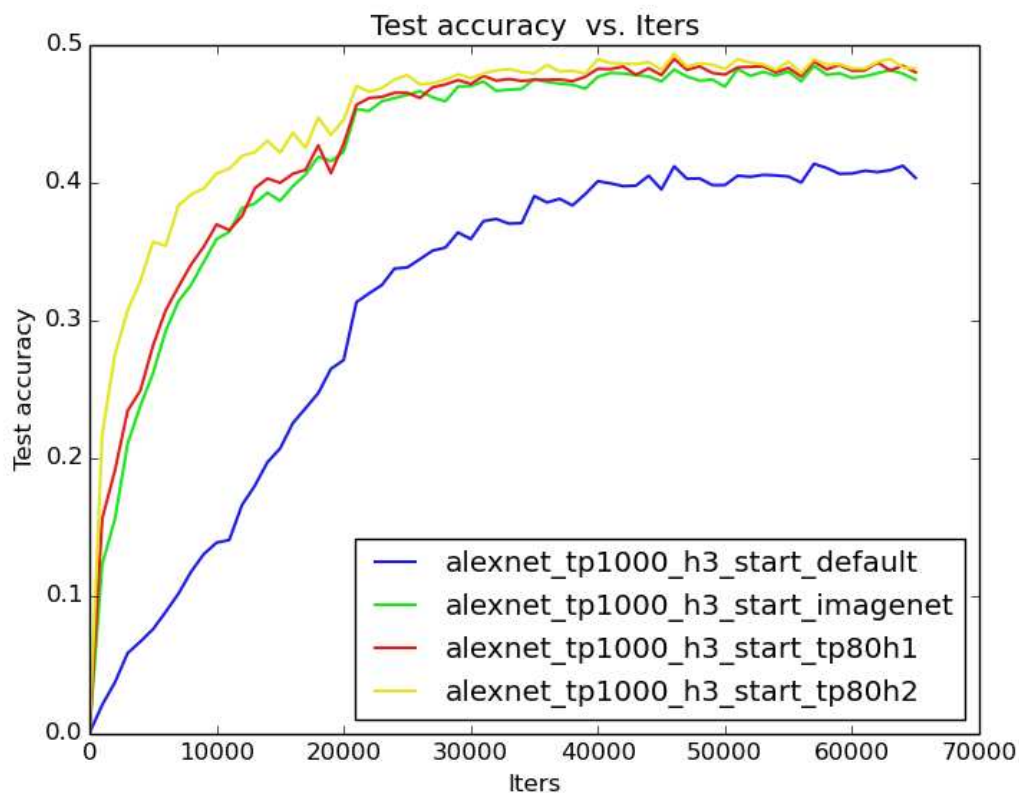
- randomly initialized (alexnet\_tp80\_h2\_start\_default)
- fine-tuned from the ImageNet dataset (alexnet\_tp80\_h2\_start\_imagenet)
- fine-tuned from the document-level-h1 image-topic classification model (alexnet\_tp80\_h2\_start\_tp80h1)

These plots show that

- Fine-tuning from a good initialization (even cross image modalities) is better than starting from the scratch. (alexnet\_tp80\_h2\_start\_imagenet > alexnet\_tp80\_h2\_start\_default)
- Fine-tuning from a more closely related task CNN model is even better than fine-tuning from less related task model. (alexnet\_tp80\_h2\_start\_tp80h1 > alexnet\_tp80\_h2\_start\_imagenet)



### (2.3) sentence-level-h3 image-topic classification



The sentence-level image-topic classification accuracy plots using variations of AlexNet 8-layers show that

- It is beneficial to start from ImageNet CNN weights.
- Using the most relevant weights (document-level-h2) task model helps the curve to converge more quickly and reach a higher accuracy, but the final performance difference is less than what previously observed.

## 5. Radiologist's analysis of document-level 80 topics

<b>Class-ID</b>	<b>Document-level-h1 Class Description (by two experienced board-certified Radiologists)</b>	<b>Images #</b>
<b>0</b>	Most terms refer to DEXA (absorptiometry, nuclear, densitometry) but there are CT images and cross-sectional imaging terms (MRI).	12
<b>1</b>	Interval follow-up on cancer patient, with many cancer tumor images in different body regions (CT/MRI).	10145
<b>2</b>	Lesions in solid abdominal organs, primarily kidney (CT/MRI).	2335
<b>3</b>	Chest instrumentation on CT.	3
<b>4</b>	MRI of brain tumor.	266
<b>5</b>	Abdominal ultrasound.	0
<b>6</b>	PET, PET/CT (mostly chest)	8
<b>7</b>	Abdominal MRI in many imaging sequences, but no specific disease terms.	4860
<b>8</b>	Normal Chest/Abdomen CT images.	361
<b>9</b>	Interval follow-up on abdominal neoplasm (CT/MRI).	3392
<b>10</b>	CT of pulmonary diseases.	2542
<b>11</b>	Abdomen, brain PET.	80
<b>12</b>	Postsurgical brain MRI.	70
<b>13</b>	Normal brain MRI.	294
<b>14</b>	Lower extremity MRI (pelvis, knee and legs).	29
<b>15</b>	Brain and spinal MRI (different field of views).	774
<b>16</b>	Pulmonary diseases (CT/MRI).	76
<b>17</b>	Breast imaging MRI.	203
<b>18</b>	Coronary artery calcium scoring (CT/MRI).	217
<b>19</b>	Renal disease (CT/MRI).	19
<b>20</b>	Spine degenerative disease (CT/MRI)	4
<b>21</b>	Metastatic liver disease (CT/MRI) [Primary tumors which metastasize to liver (melanoma, lung) with numerous liver terms.]	5917
<b>22</b>	Neck CT.	747
<b>23</b>	Inner ear neoplasm (CT/MRI).	100
<b>24</b>	Advanced degenerative spine disease CT. [Terms to suggest advanced stage (fracture, compression, deformity, multiple, osteopenia, kyphosis).]	3
<b>25</b>	Anterior skull base neoplasm MRI.	299
<b>26</b>	PET.	10
<b>27</b>	Cerebellar neoplasm MRI.	224
<b>28</b>	DEXA (Dual-energy X-ray absorptiometry).	0
<b>29</b>	Gastrointestinal tract disease CT.	1394
<b>30</b>	Metastatic diseases (masses, adenopathy, nodules) in Chest and Abdomen (CT/MRI).	3626
<b>31</b>	Degenerative disc diseases (spine) in MRI.	585
<b>32</b>	Full body screening of diffuse diseases (MRI/CT).	29
<b>33</b>	Prostate MRI.	63
<b>34</b>	Central venous catheter placement CT.	18
<b>35</b>	CT performed to detect interval changes, most likely in the postoperative period.	2
<b>36</b>	Brain tumor MRI (a small portion of images are PET with lower spatial resolution).	387
<b>37</b>	CT performed to acute respiratory symptoms in the setting of a chronic disease.	137
<b>38</b>	Report headers (MRI/CT of all body regions). [These are terms that appear in almost all reports as headers. It is unclear to the physician why this became a separate category, and how these specific images became linked with this category.]	278
<b>39</b>	MRA (MR Angiography) of neck.	14
<b>40</b>	Cardiac stress test CT.	3
<b>41</b>	Metastatic disease follow-up examinations (CT/MRI).	59

42	Brain imaging (MRI/CT).	1149
43	Interventional procedure, vascular/nonvascular mixed (CT)	324
44	Normal Brain MRI.	110
45	Lymphadenopathy (CT/MRI)	115
46	Cross-sectional imaging (CT/MRI)	22687
47	Sinus diseases (CT/MRI)	93
48	Follow-up CT imaging with diseases (lymphadenopathy, nodularity, thickening, hypodensity, lesions)	18939
49	DEXA (Dual-energy X-ray absorptiometry).	0
50	Abdominal cross-sectional CT imaging (normal)	2937
51	Assessment of disease progression in CT imaging. (more/slightly, prominent, greater, extensive, smaller, diffuse, relatively, similar, compared)	3
52	DEXA (Dual-energy X-ray absorptiometry).	0
53	Interpretation of examinations of outside hospital examinations (CT/MRI).	2341
54	Venous thrombosis (CT/MRI).	16
55	Bone scans (MDP).	3
56	Lesions with unspecific features and cannot be characterized (CT/MRI).	6625
57	Non-standard chest imaging. [Terms which indicate view is obstructed] (CT/MRI).	38
58	Renal scintigraphy CT.	25
59	Research study PET.	0
60	Bone age study.	0
61	Brain tumor protocol MRI.	11
62	Live CT/MRI.	348
63	Pelvic CT/MRI.	357
64	Liver tumor in follow-up studies (CT/MRI).	117
65	Fluoroscopically guided intervention, lumbar puncture or central venous catheter placement.	0
66	Chest radiograph template.	0
67	Neurofibromatosis protocol imaging (CT/MRI).	517
68	Imaging studies for interval changes for chest/liver/brain (CT/MRI).	477
69	Arthritis MRI imaging (hand/foot/ankle/joint).	142
70	Follow-up chest/liver imaging (CT/MRI).	415
71	Image-guided liver biopsy CT.	56
72	Indeterminant lesion in chest/liver/abdomen (CT/MRI)	93
73	Reporting critical findings in liver/heart/lung (CT/MRI)	1369
74	Instrumentation artifact limiting interpretation (abdomen MRI)	16
75	Brain MRI imaging.	82
76	DEXA (Dual-energy X-ray absorptiometry).	0
77	Lymphadenopathy, Metastatic diseases (liver/lung/pelvis/kidney/head-neck, CT/MRI).	113037
78	Bone metastases (CT/MRI)	428
79	Uncertainty/equivocation in imaging diagnosis (cross-section CT/MRI)	222

**Notation:** Class 38 is uncertain why this forms a cluster by LDA document topic model based clustering; Classes 48, 51, 56, 57, 72, 73, 74, 79 indicates the **higher level classes of diagnostic/reasoning concepts** beyond regular anatomy and pathology findings; all **other classes** are dominantly based on the anatomy and/or pathology findings, often cross CT/MRI modalities. **Rare imaging modalities** (e.g., DEXA, ultrasound, Fluoroscopies) performed at the studied hospital have no key images stored in the PACS system.

## 6. Topics, terms (keywords), images by using LDA topic models on radiology reports

### ■ Note that

- \*\* indicates potential higher-level concept
- \* indicates variable suffix
- degree of confidence that the word cluster represents the concept:
  - 1: low, 2: moderate, 3: high
- the actual visual diversity is much higher than the sampled images (only for illustration purpose)

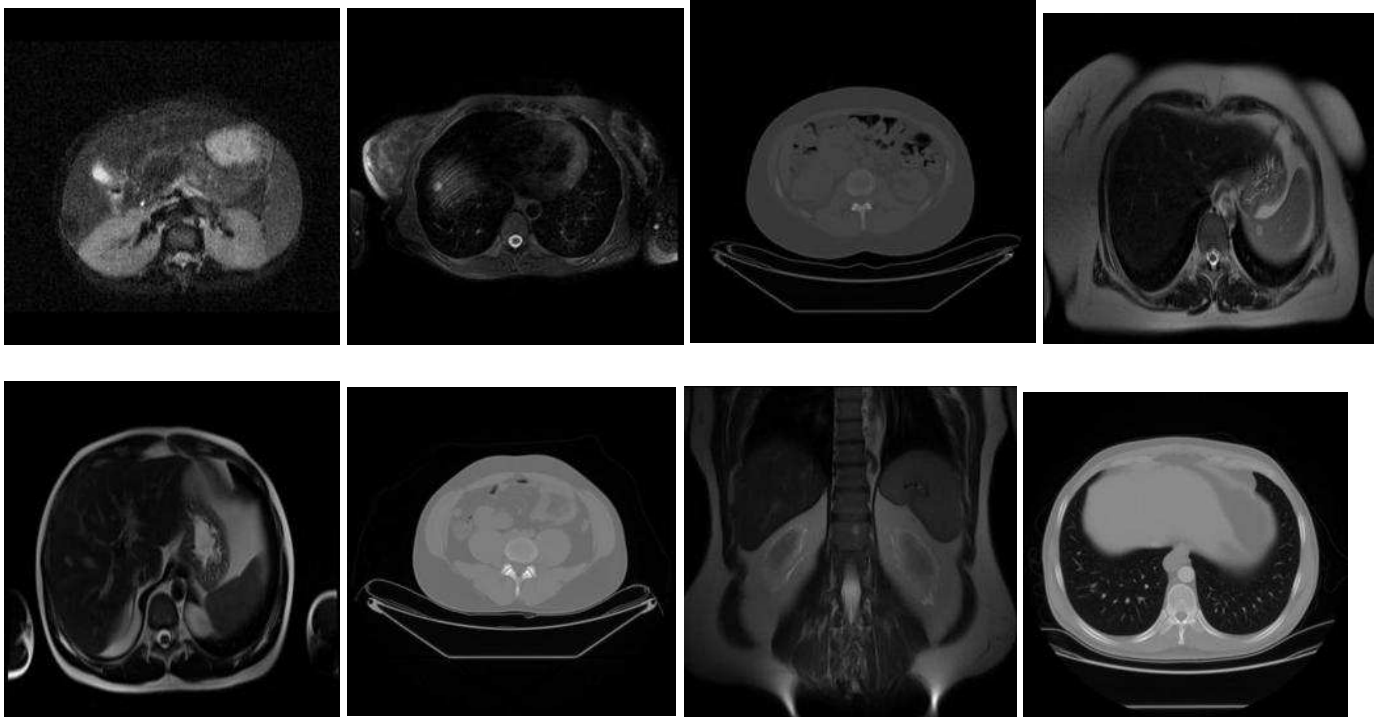
### Topic 00:

- DEXA. 2. [Most terms refer to DEXA (absorptiometry, nuclear, densitometry) but there are CT images and cross-sectional imaging terms (MRI).]

- terms:

was,performed,protocol,fat,impression,per,research,bone,image,processing,abdomen,were,density,measurements,will,subcutaneous,determine,measurement,volume,patient,obtained,dual,visceral,scheduled,mineral,energy,absorptiometry,initial,given,level,purposes,volunteer,data,analysis,slice,followup,adipose,mri,scan,available,intra-abdominal,medicine,nuclear,appointment,provided,service,did,densitometry,single,images

- images:



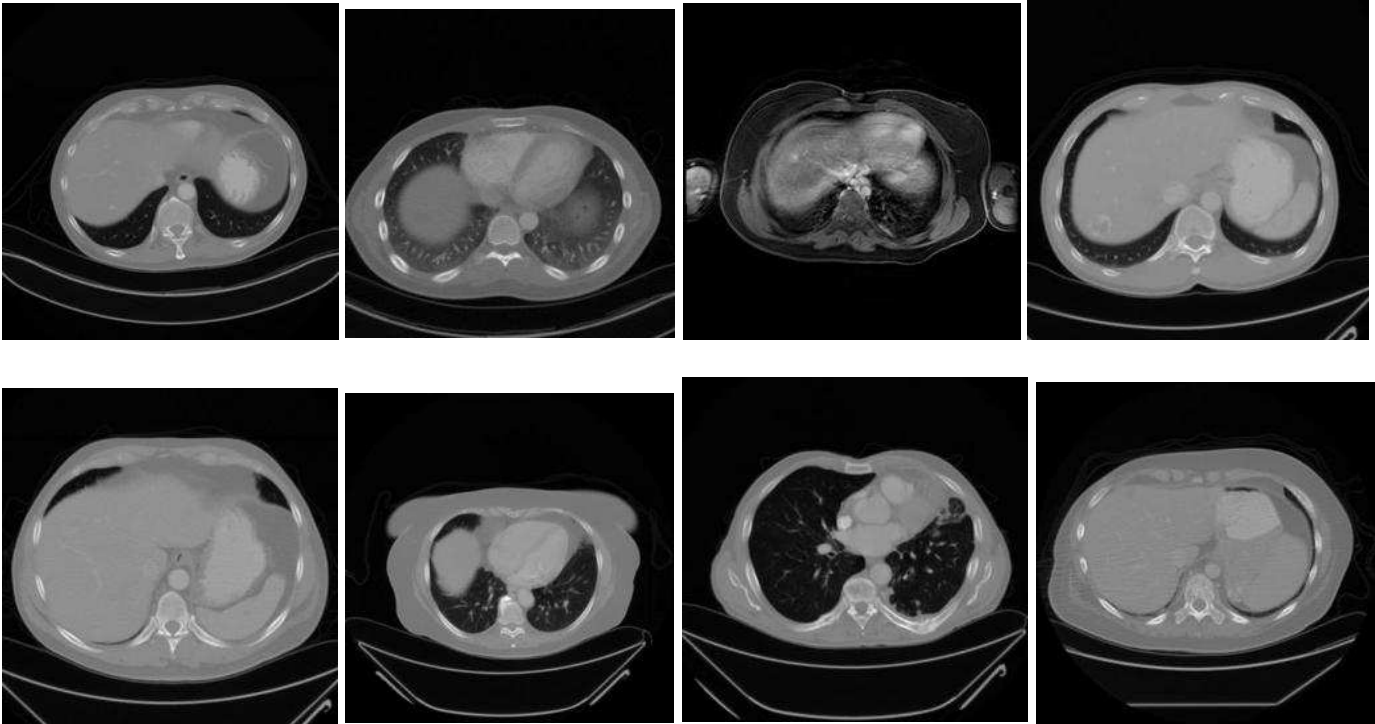
### Topic 01:

- Interval follow-up on cancer patient. 2. (difference, development, mass)

- terms:

include,findings,evidence,change,not,difference,technique,made,comparison,interim,seen,were,scans,obtained,abdominal,lung,since,intravenous,attributable,injection,indication,enlargement,consistent,mass,developing,previous,due,about,mediastinal,renal,liver,changes,impression,thoracic,splenic,surgery,pelvic,definite,additional,administered,isovue,retroperitoneal,including,development,suggesting,multiple,without,node,from,content

- images:



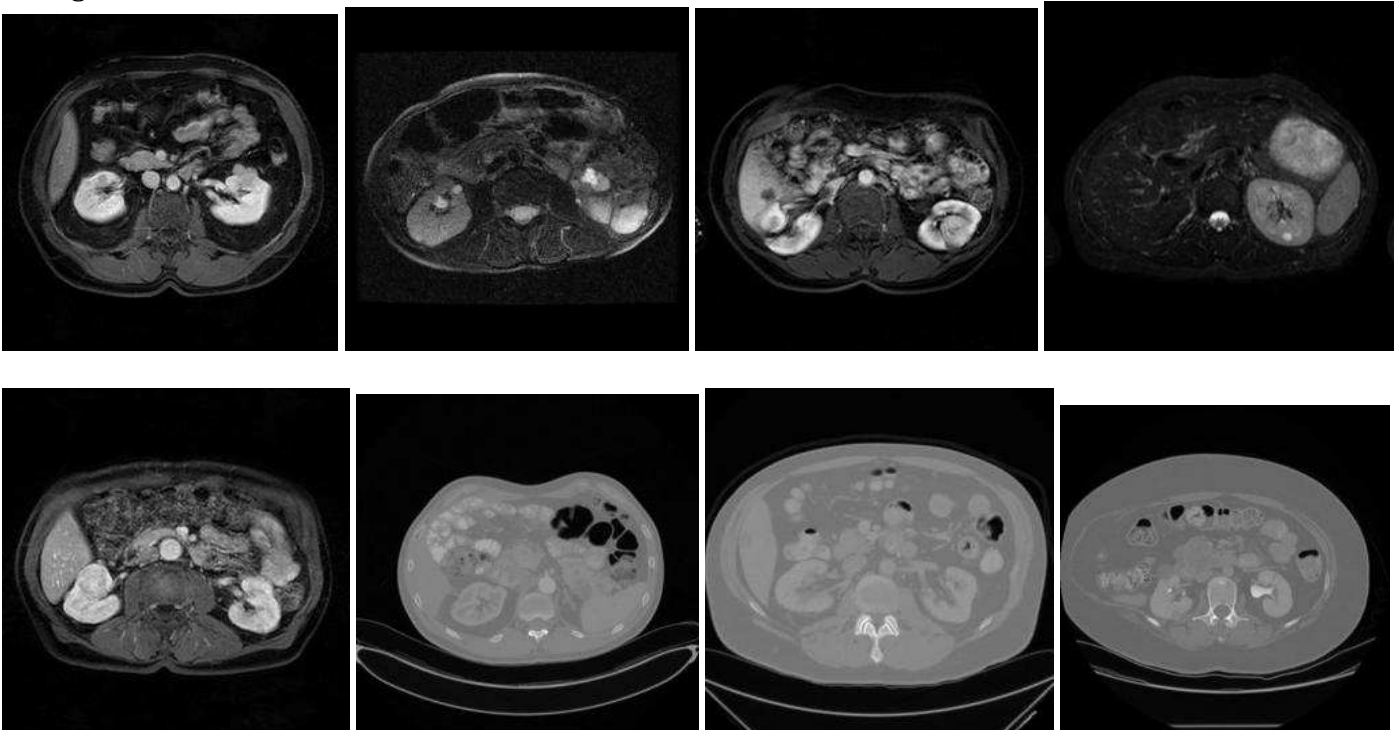
## Topic 02:

- Lesions in solid abdominal organs, primarily kidney. 2. [There is a preponderance of kidney terms (kidney, renal, adrenal, pole, vhl, nephrectomy, rcc).]

- terms:

kidney,renal,adrenal,mass,lesion,lesions,cysts,pole,cystic,solid,cyst,pancreas,pancreatic,abdomen,nephrectomy,multiple,upper,enhancing,liver,lower,masses,small,phase,gland,bilateral,vhl,please,partial,head,evaluate,complex,compare,tail,mid,characterize,imaging,prior,spleen,glands,impression,contrast,rcc,too,tumor,from,arterial,post,consistent,two,largest

- images:



### Topic 03:

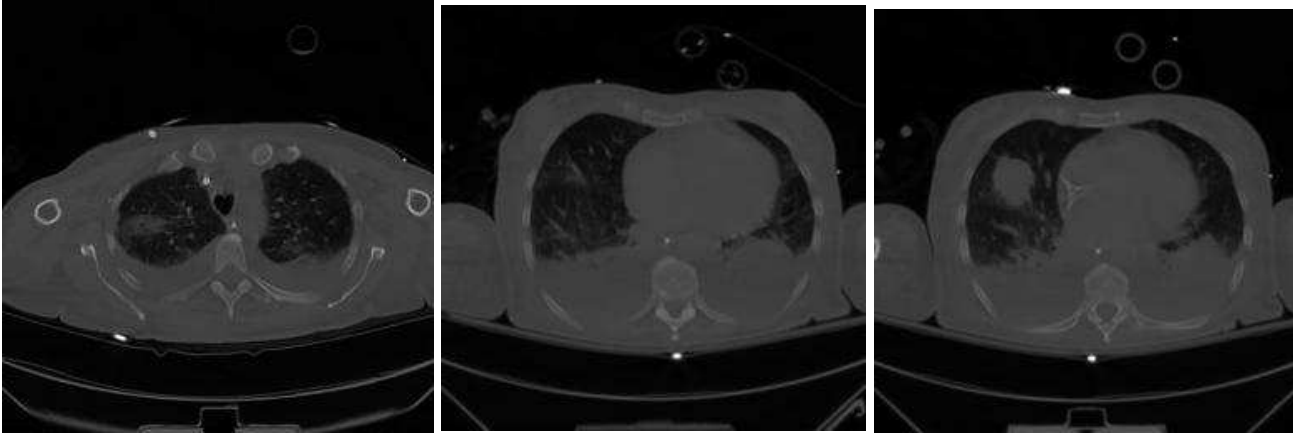
- Chest instrumentation on CT. 3. (tube\*, line\*, nasogastric, catheter, endotracheal, tip, tracheostomy)

- terms:

chest, tube, portable, a.m, infiltrates, lung, bilateral, p.m, film, unchanged, line, nasogastric, catheter, endotracheal, x-

ray, pneumothorax, view, place, single, findings, central, position, tubes, day, comparison, infiltrate, heart, placement, tip, diffuse, impression, pulmonary, lungs, examination, remains, carina, dated, mediastinum, demonstrates, edema, devices, tracheostomy, lines, change, support, history, from, patient, earlier, above

- images:



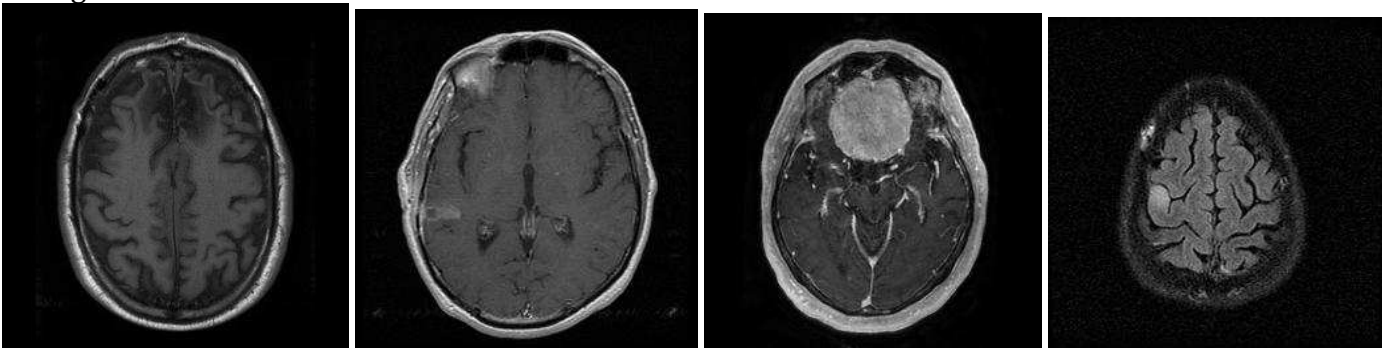
### Topic 04:

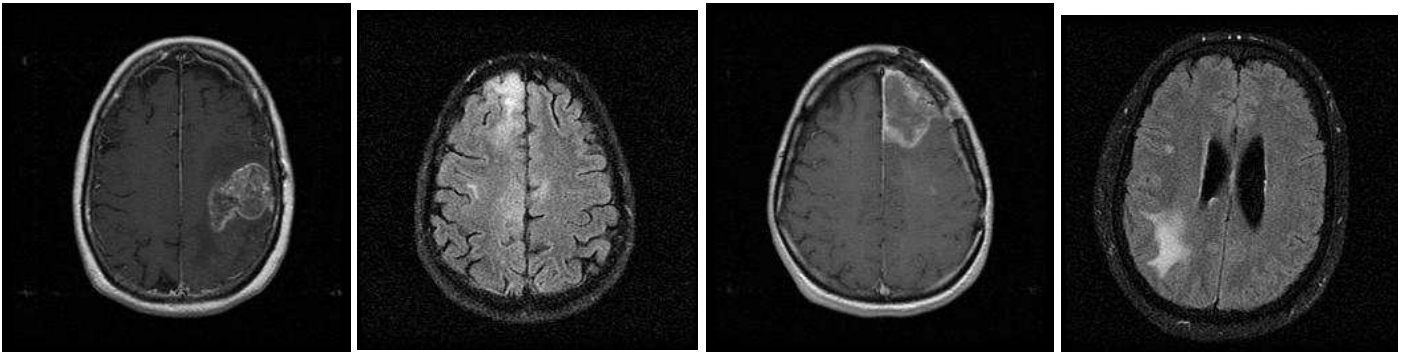
- MRI of brain tumor. 3. [Tumor-specific terms (mass, progression, stable, resection) and MR specific terms (mri, flair, tesla, fse, diffusion, gradient, echo, weighted, 1.5, T1-FFE, magnevist).]

- terms:

axial, contrast, mri, sagittal, post, flair, enhancement, blood, dynamic, brain, relative, volume, this, precontrast, from, tesla, fse, diffusion, gradient, resection, comparisons, maps, philips, progression, some, susceptibility, perfusion, stable, achieve, technique, echo, weighted, 1.5, evidence, mass, findings, hemorrhage, enhanced, impression, frontal, signal, coronal, dti, tumor, t1-ffe, hydrocephalus, magnevist, reformations, bolus, lesion

- images:



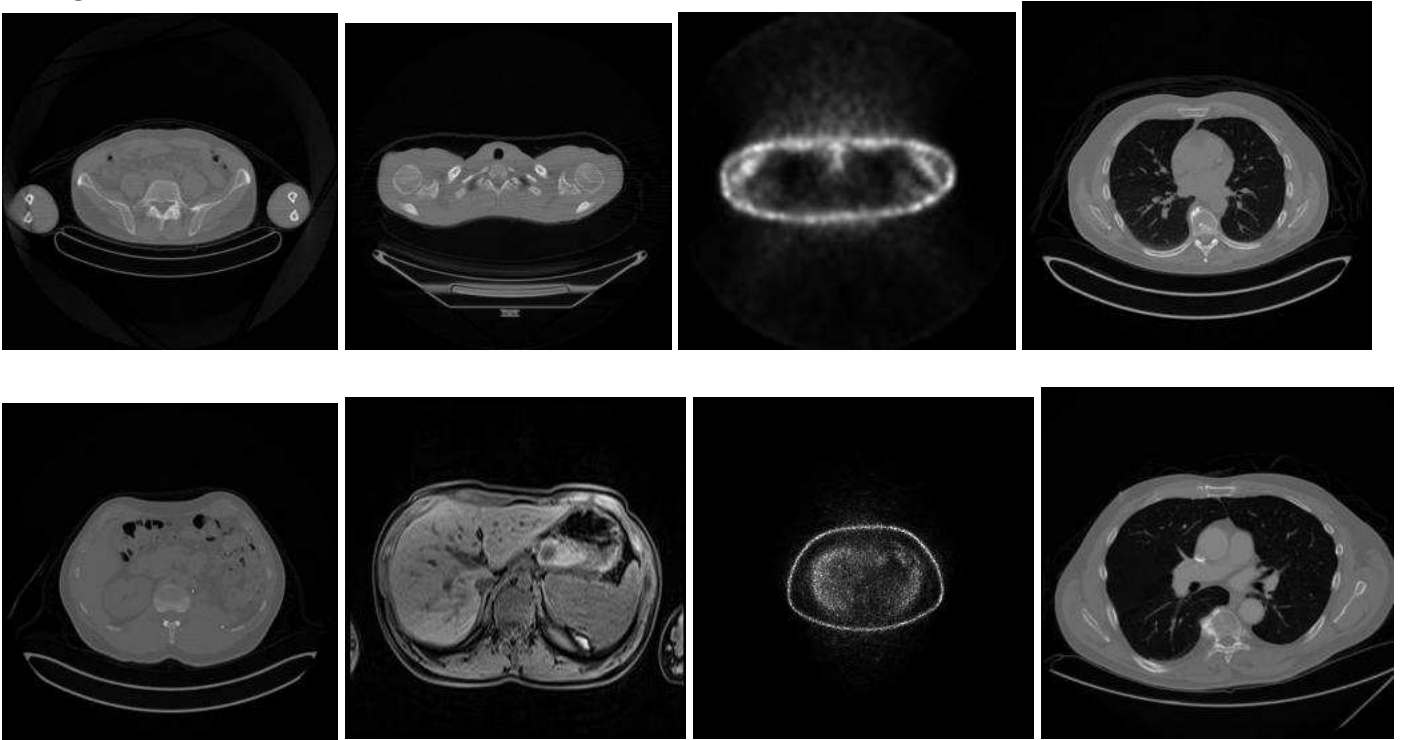


**Topic 05:**

- Abdominal ultrasound. 3. [Ultrasound specific terms (Doppler, colorflow, duplex, echogenic).]  
 - terms:  
 fluid, collection, evidence, approximate, review, mass, ultrasound, without, perinephric, compatible, conducted  
 , time, suite, nontender, hydronephrosis, real, real-  
 time, overlying, doppler, hematoma, comparison, perihepatic, demonstrated, calculus, definite, span, impressio  
 n, dilation, since, obscured, main, perisplenic, gas, kidney, kidneys, patient, bowel, flow, color-  
 flow, due, foci, spleen, duplex, focus, minimal, portion, direction, lesser, echogenic, sac  
 - images:  
 NO IMAGE AVAILABLE

**Topic 06:**

- PET. 3. [PET specific terms (FDG, activity, uptake, SUV\*, hypermetabolic, glucose/administration).]  
 - terms:  
 fdg, was, activity, uptake, suv, pet, scan, from, body, attenuation, mci, localization, minutes, upper, focus, correctio  
 n, hypermetabolic, mg/dl, glucose, administration, maximum, obtained, blood, weight, skull, were, imaging, base  
 , prior, max, abnormal, thighs, after, suvmax, value, region, dose, head, time, physiologic, history, procedure, base  
 d, which, findings, liver, focal, indication, intense, performed  
 - images:





### Topic 07:

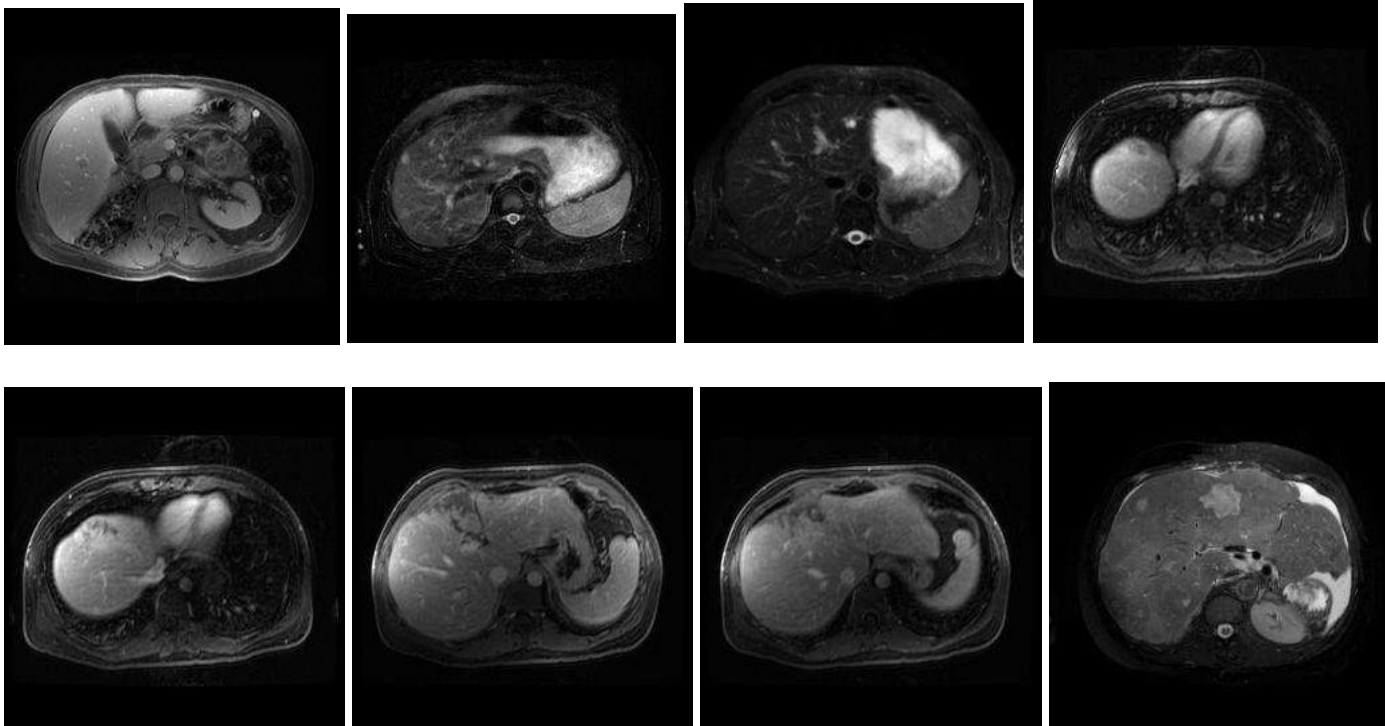
- MR, generic. 3. [MR specific terms (MR, t1-weighted, t2-weighted, stir, sequences, gadolinium, 1.5, tesla, gradient, spin, phase, hyperintense) though no disease terms.]

- terms:

mri,axial,signal,coronal,images,imaging,t1-weighted,t2-weighted,fat,sequences,stir,magnevist,echo,gadolinium,findings,enhancement,technique,intensity,marrow,sequence,1.5,tesla,impression,prior,contrast,comparison,was,bright,history,without,weighted,gradient,saturation,suppression,fast,post,spin,phase,following,evidence,series,hyperintense,fat-

suppressed,after,done,including,administration,out,muscle,characteristic

- images:



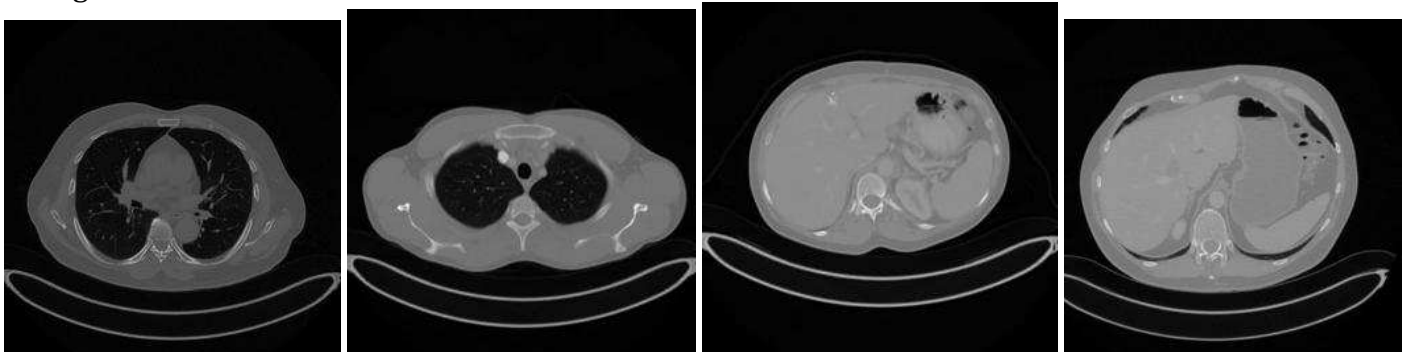
### Topic 08:

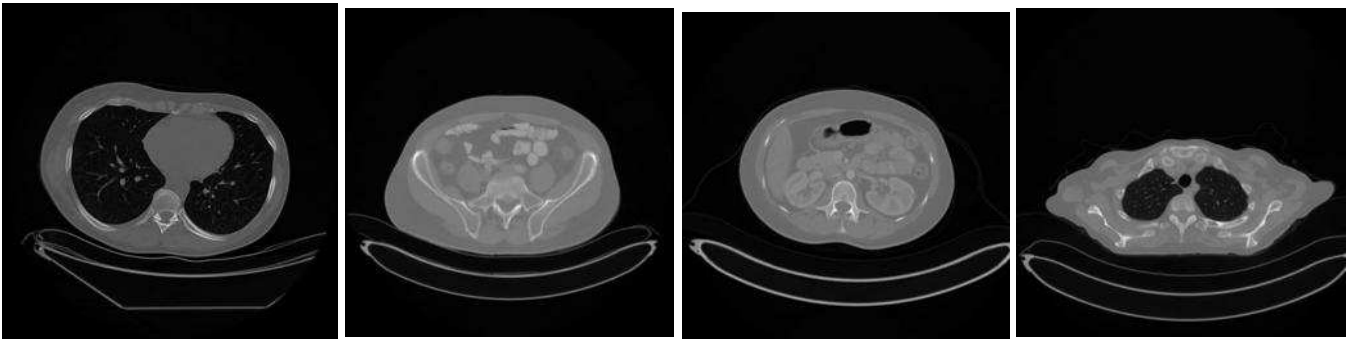
- CT, not otherwise specified. 2. [No specific disease terms. Terms appear “positive” (normal, within/limits, otherwise, free).]

- terms:

normal,within,limits,structures,impression,heart,mediastinum,lungs,soft,tissues,osseous,size,clear,evidence,bony,comparison,chest,intact,vessels,disease,bones,upper,great,seen,visualized,appear,otherwise,negative,active,findings,abdomen,free,age,none,evaluation,appearance,organs,lat,available,top,pbsct,radiographic,pre-transplant,other,studies,abnormalities,cxr,thorax,apices,present

- images:





### Topic 09:

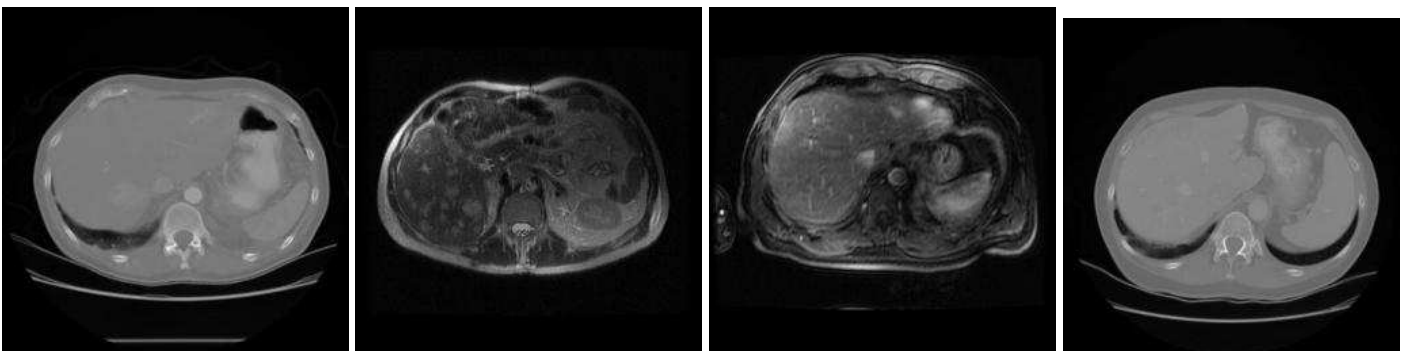
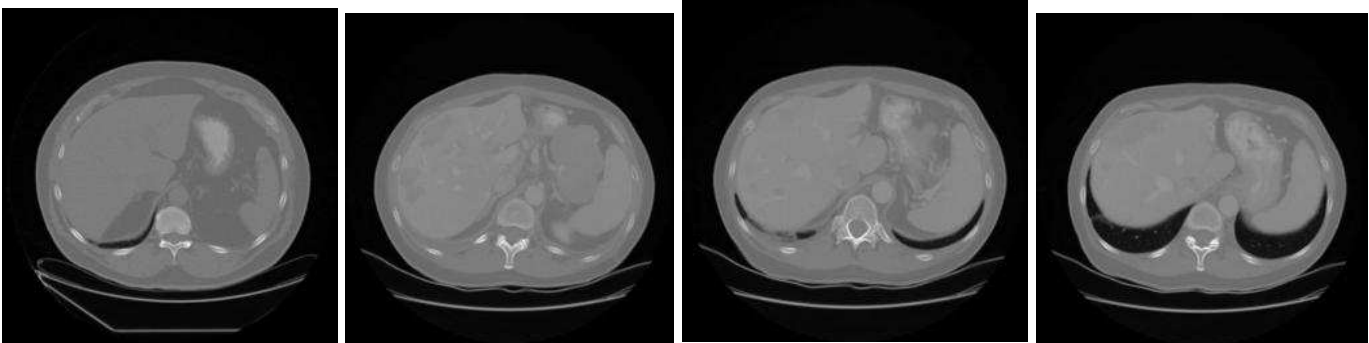
- Follow-up on abdominal neoplasm. 2. [Terms regarding change (unchanged, changes, comparison) imply a follow-up examination.]

- terms:

abdomen,chest,size,small,pelvis,pelvic,contrast,liver,procedure,without,adenopathy,complication,lesions,focal,administered,enteric,mass,iso-

300,during,findings,apparent,unchanged,negative,spleen,about,infusion,few,130,lungs,lung,impression,retroperitoneum,adrenal,lesion,density,post,changes,comparison,low,postcontrast,bowel,mediastinal,kidneys,retroperitoneal,glands,stable,attenuation,masses,mesentery,upper

- images:



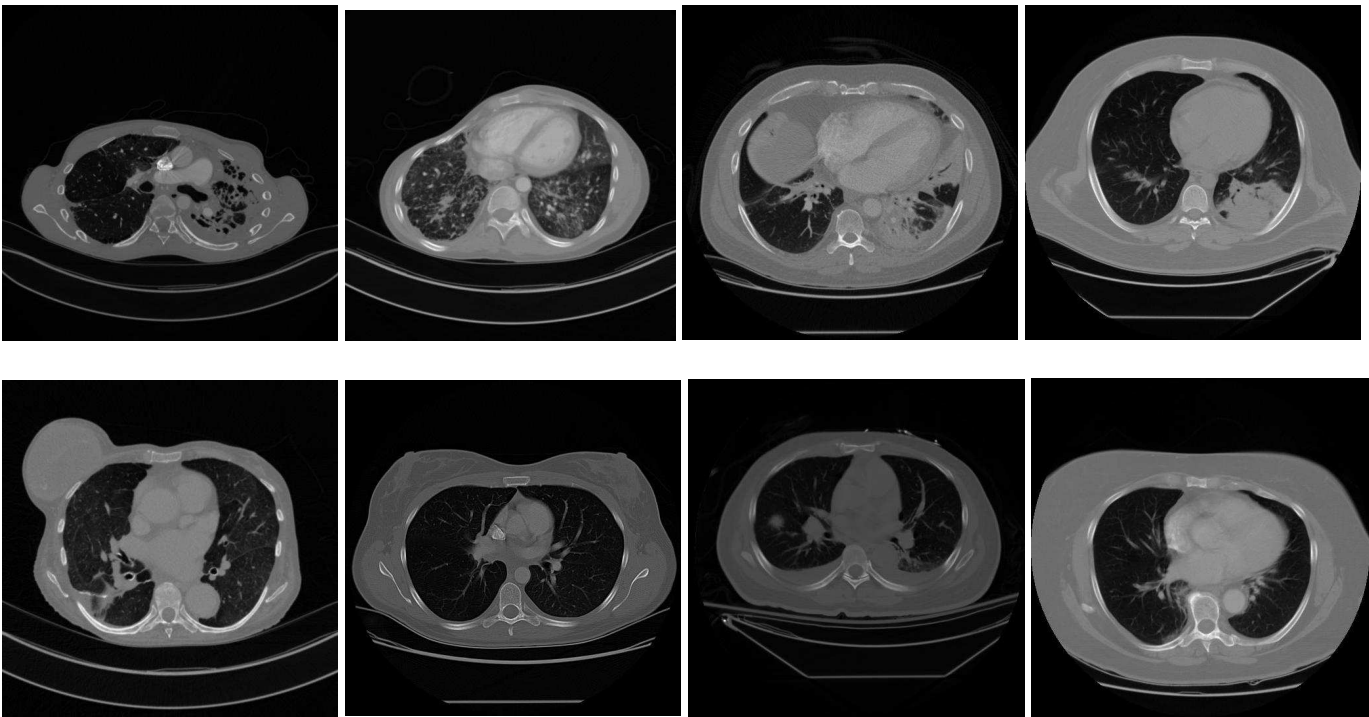
### Topic 10:

- CT of pulmonary disease. 3.

- terms:

lobe,lung,upper,lower,chest,pulmonary,infiltrate,middle,scarring,disease,findings,consolidation,new,impression,nodular,interstitial,infiltrates,mediastinal,nodules,resolution,bronchiectasis,bilateral,calcified,lungs,fibrosis,opacities,nodule,areas,high,pleural,atelectasis,linear,lobes,mediastinum,hilar,parenchymal,comparison,focal,density,scattered,calcifications,opacity,without,patchy,densities,prone,contrast,small,history,noncontrast

- images:



**Topic 11:**

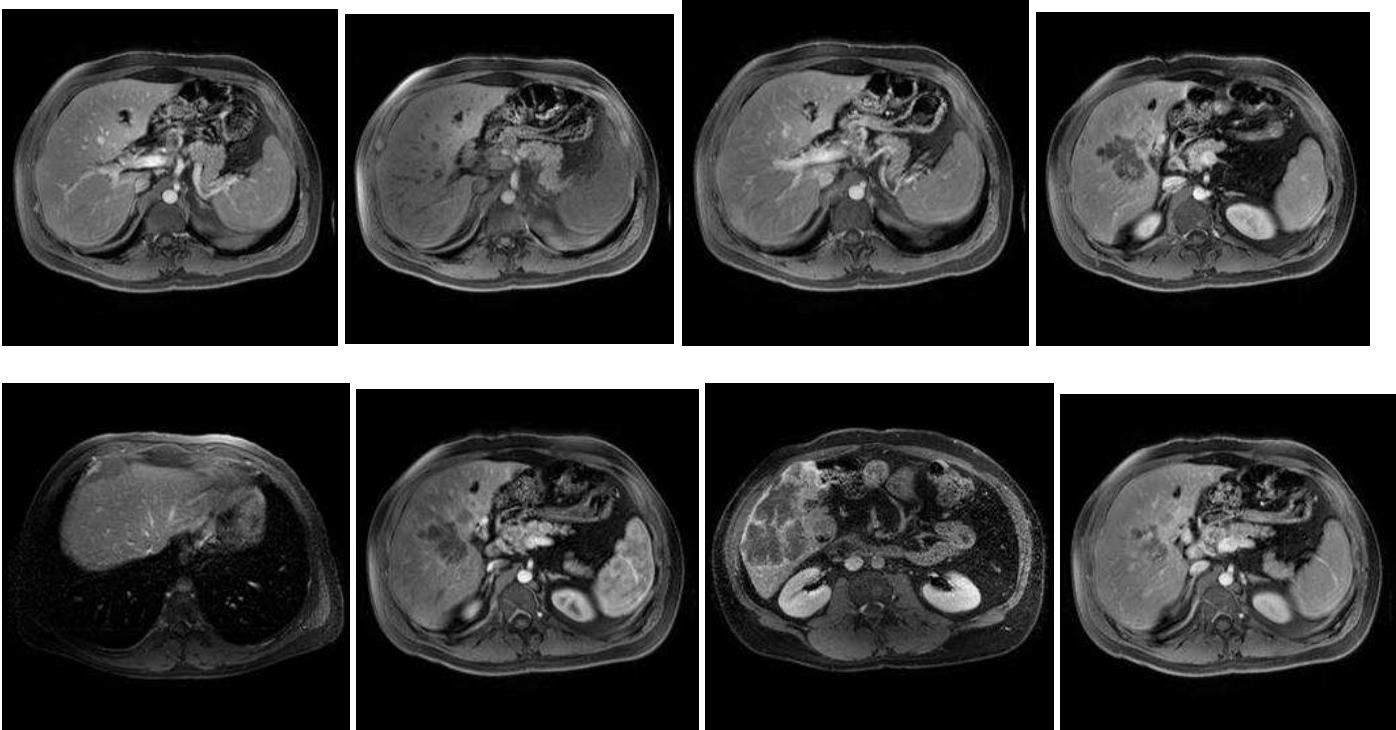
- PET/CT. 3.

- terms:

uptake,pet,today,increased,fdg,patient,images,this,show,radionuclide,approximately,was,intravenous,prior,following,f-

18,administration,mci,tissue,torso,not,localization,hour,abnormal,done,nih,were,which,impression,pet/ct,tracer,suv,one,has,performed,glucose,those,only,comment,attenuation,about,corresponding,blood,appears,measured,purposes,data,correction,similar,radiopharmaceutical

- images:



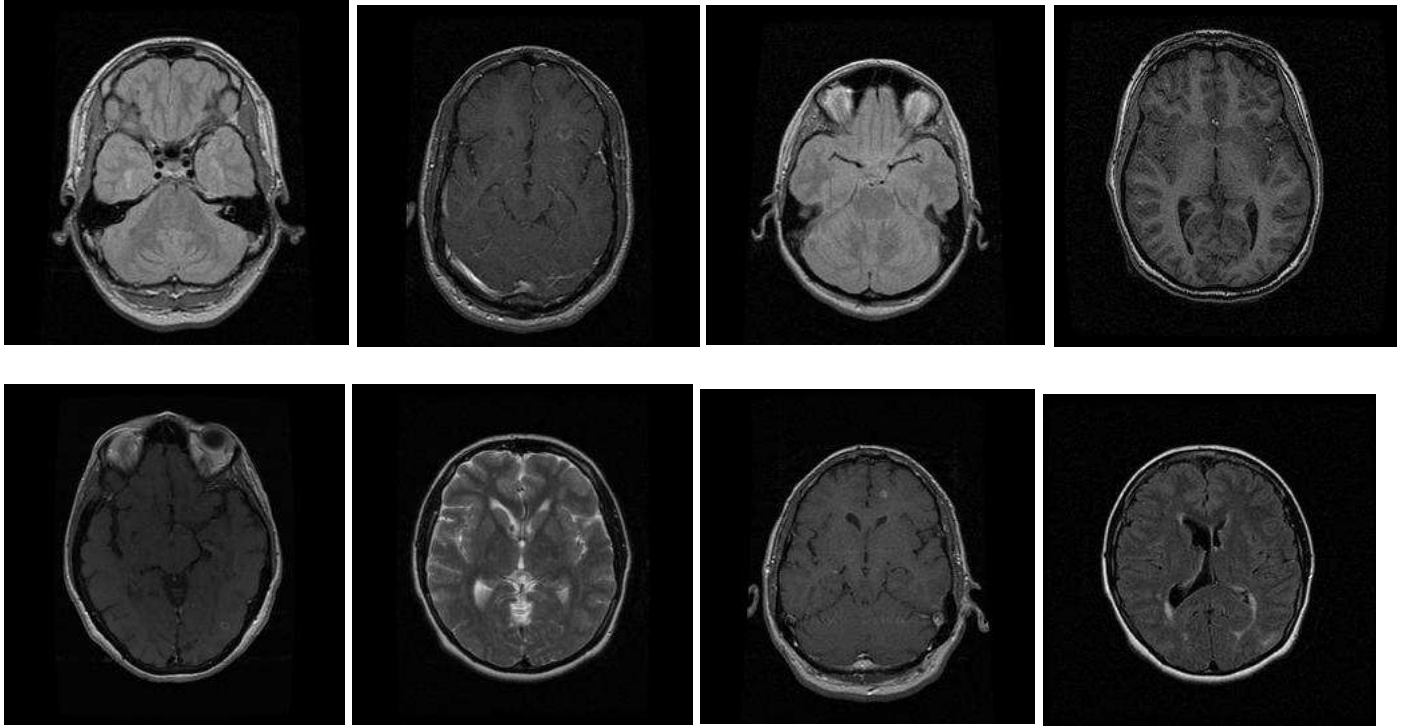
## Topic 12:

- Postsurgical brain. 2. [Lesion descriptors often associated with surgical/radiation changes (sclerosis, infarct, hemorrhage).]

- terms:

lesions,multiple,lesion,sclerosis,appear,enhancing,findings,contrast,mri,brain,new,these,prior,technique,evidence,comparison,periventricular,following,impression,white,multisequence,identified,major,matter,mild,protocol,injection,multiplanar,foci,enhancement,moderate,intracranial,prominent,infarct,patent,normal,orbits,air,ventricles,infratentorial,hemorrhage,sulci,mass,paranasal,mastoid,present,typical,inflammation,juxtacortical,volume

- images:



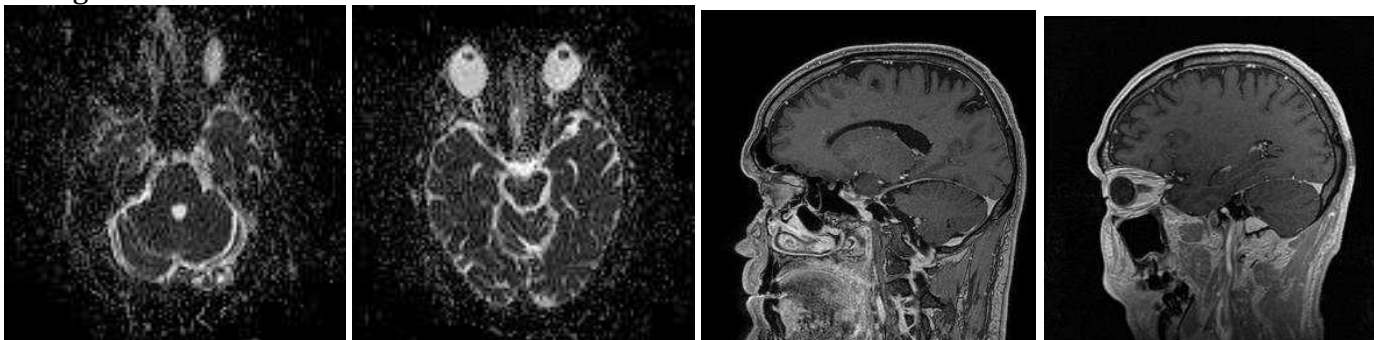
## Topic 13:

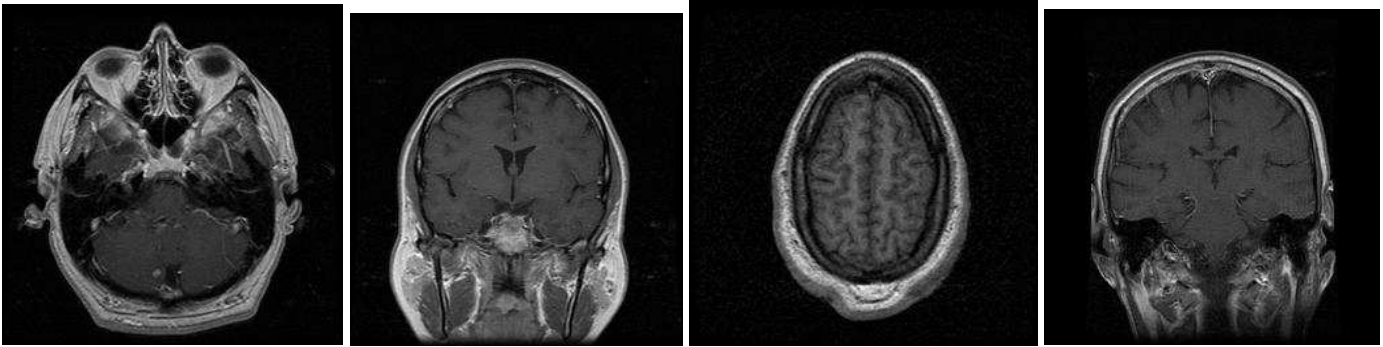
- Brain MRI. 3. [Brain anatomic terms (brain, ventricles, sulci, hemispheres, cisterns, paranasal, cerebral, flow/voids, orbits, globes) without disease terms.]

- terms:

normal,axial,brain,ventricles,mri,technique,matter,sagittal,contrast,signal,findings,impression,white,midline,sulci,configuration,flair,shift,mass,effect,parenchymal,size,hemispheres,tesla,cisterns,unremarkable,history,symmetric,grossly,sinuses,paranasal,volunteer,cerebral,vascular,signa,abnormalities,gray,flow,voids,1.5,clear,orbits,demarcation,globes,without,evidence,abnormal,fse,gradient,proton

- images:





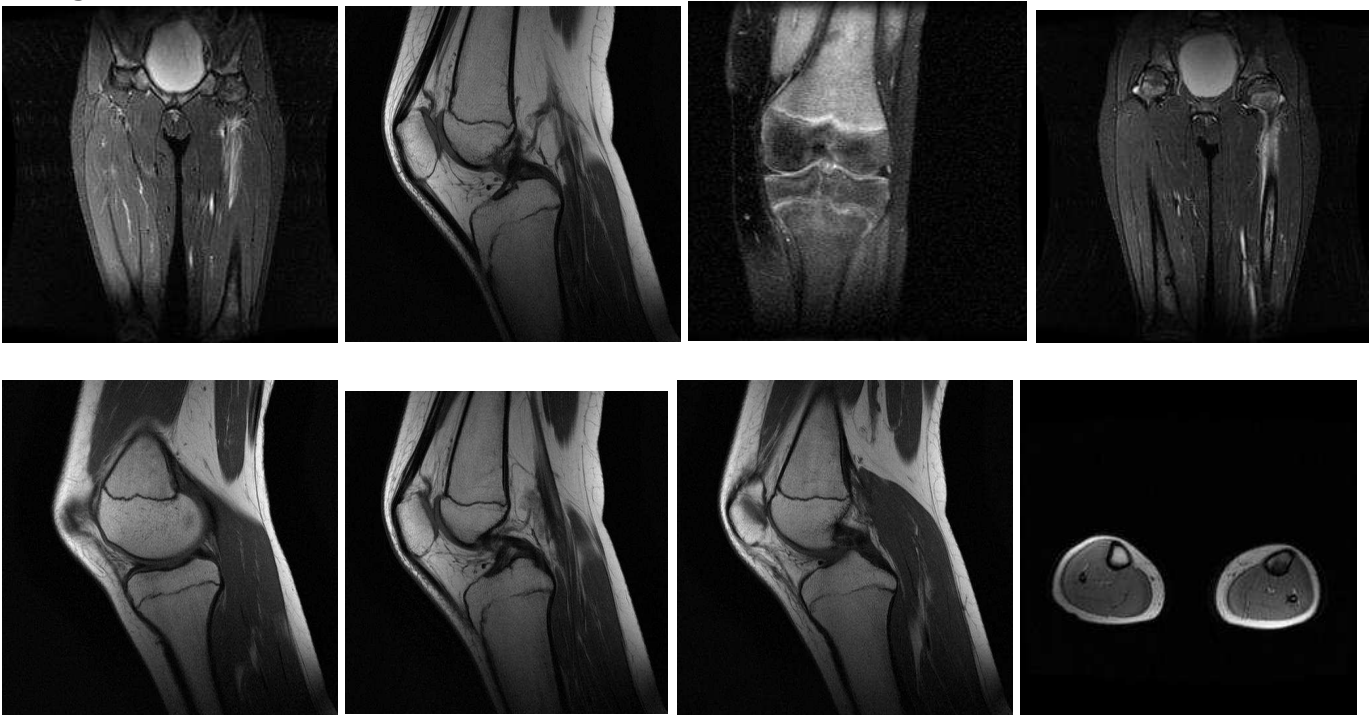## Topic 14:

- Lower extremity MRI. 3.

- terms:

bones,lower,long,distal,lateral,tibia,extremities,proximal,skull,extremity,views,femur,both,osteopenia,dysplasia,fibula,bilateral,view,fracture,femurs,upper,bone,fibrous,findings,leg,pelvis,osteogenesis,femoral,imperfecta,deformity,growth,diffuse,tibial,feet,lesions,bowing,intramedullary,hips,skeletal,mid,seen,marked,femora,bilaterally,tibias,mild,survey,impression,evidence,rod

- images:



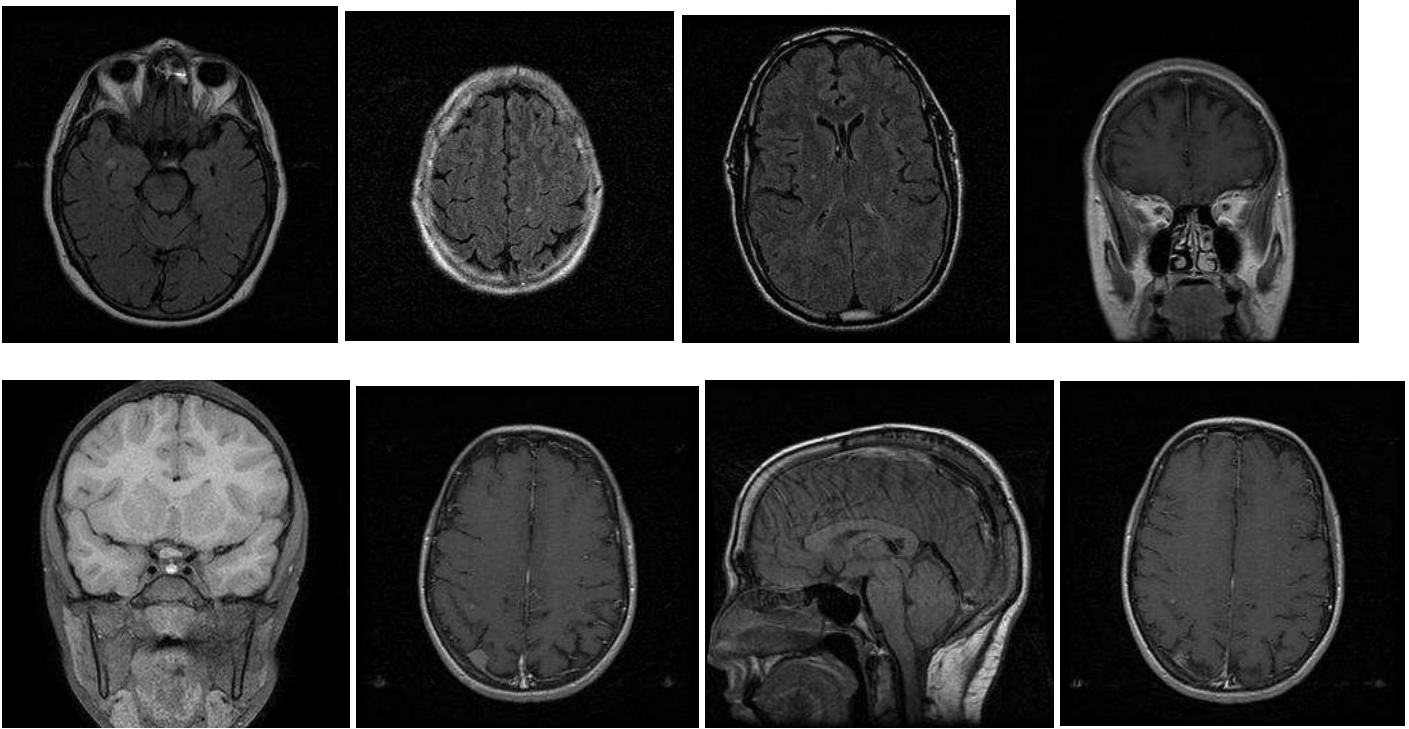
## Topic 15:

- Brain MRI, NOS. 2. [Many brain MRI terms but no disease terms.]

- terms:

identified,examination,was,brain,abnormalities,performed,noted,were,findings,technique,techniques,using,also,impression,obtained,t2-weighted,described,focal,normal,contrast,abnormality,scans,above,imaging,intravenous,magnetic, resonance,material,ventricles,both,administration,parenchyma,cerebral,after,present,hemispheres,signal,this,images,evidence,other,previous,pre,enhancement,postcontrast,appreciated,pathological,remaining,cerebellum,intensity

- images:



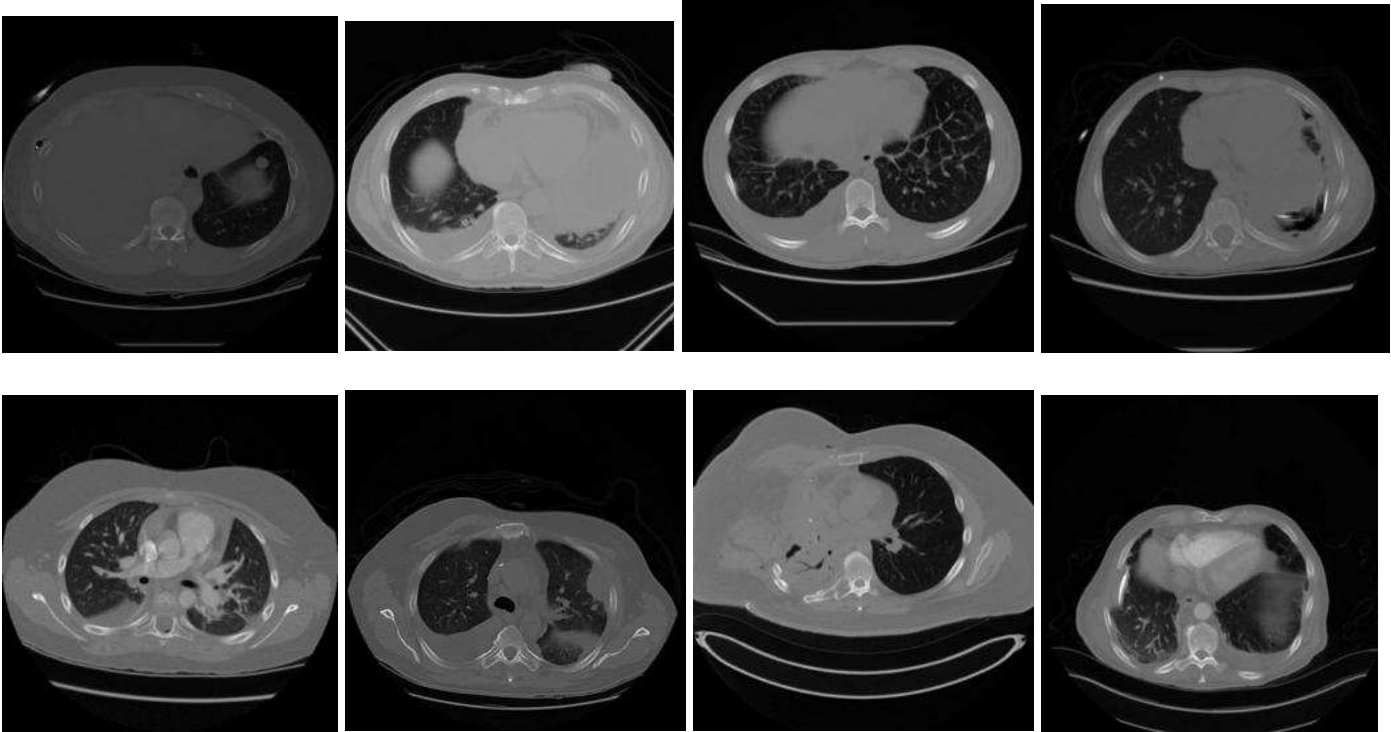
**Topic 16:**

- Pulmonary disease. 3.

- terms:

pleural,chest,lung,effusion,atelectasis,fluid,small,base,pneumothorax,lower,lateral,effusions,density,costophrenic,increased,bilateral,angle,apical,hemidiaphragm,thickening,apex,blunting,loculated,linear,upper,wall,hemothorax,findings,increasing,infiltrate,minimal,consolidation,basilar,pericardial,impression,moderate,scarring,air,changes,tubes,elevation,may,subcutaneous,due,mesothelioma,along,postoperative,posterior, right-sided,removal

- images:





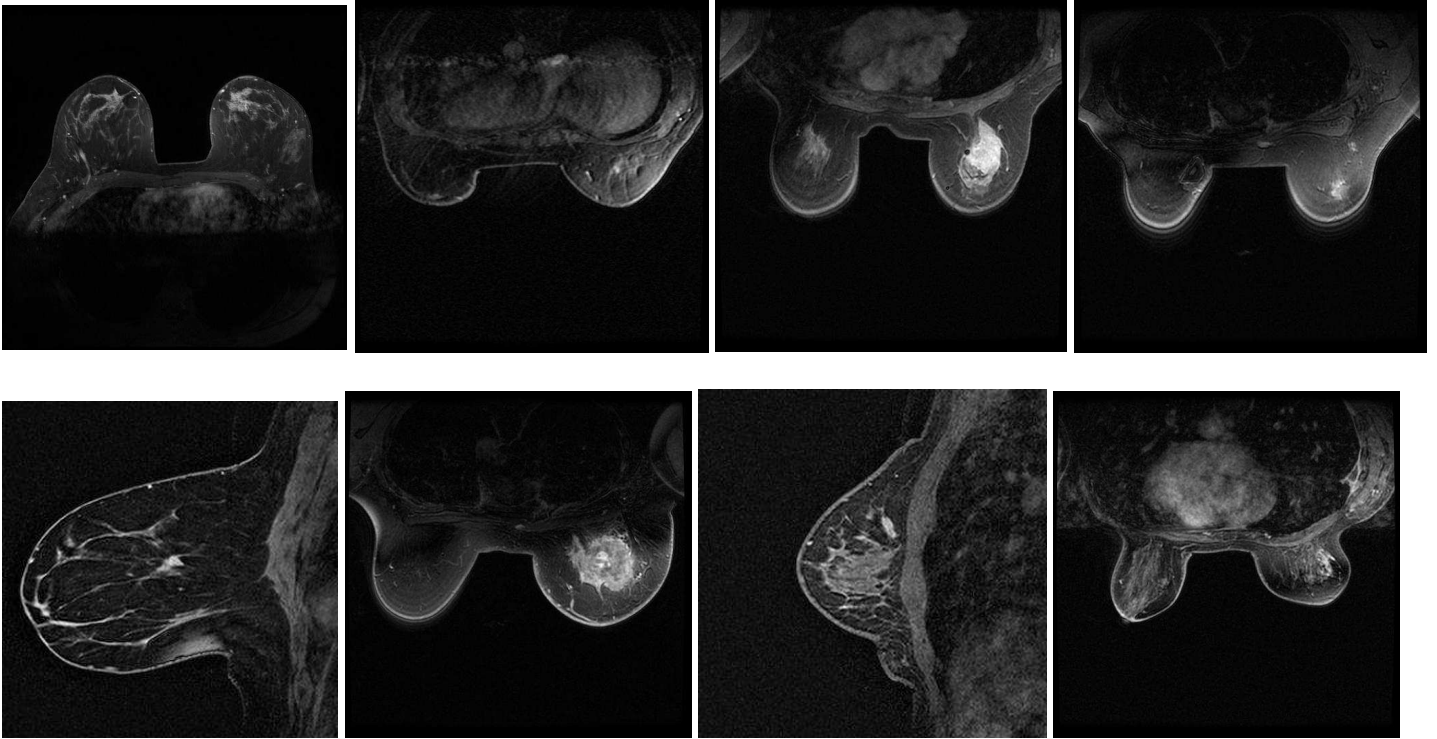
### Topic 17:

- Breast imaging. 3.

- terms:

breast,performed,suspicious,breasts,seen,impression,mass,screening,mammogram,dated,annual,cancer,mri,benign,bilateral,was,bi-rads,mammograms,negative,dense,history,calcifications,images,views,studies,quadrant,mammography,volume,organ,aspect,suggested,category,mastectomy,before,tissue,enhancement,microcalcifications,heterogeneously,prior,family,examination,recommend,malignancy,high,suggest,outer,masses,developing,clip,patient

- images:



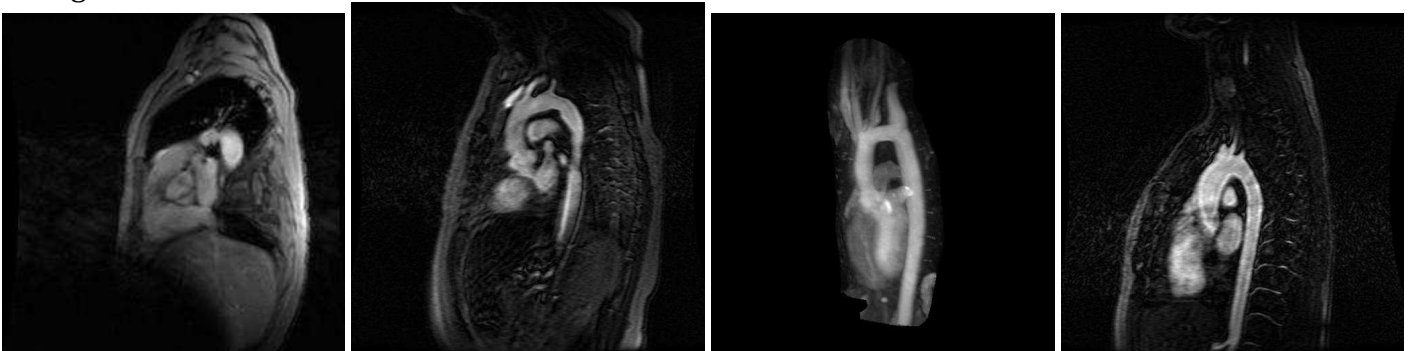
### Topic 18:

- Coronary artery calcium scoring. 3.

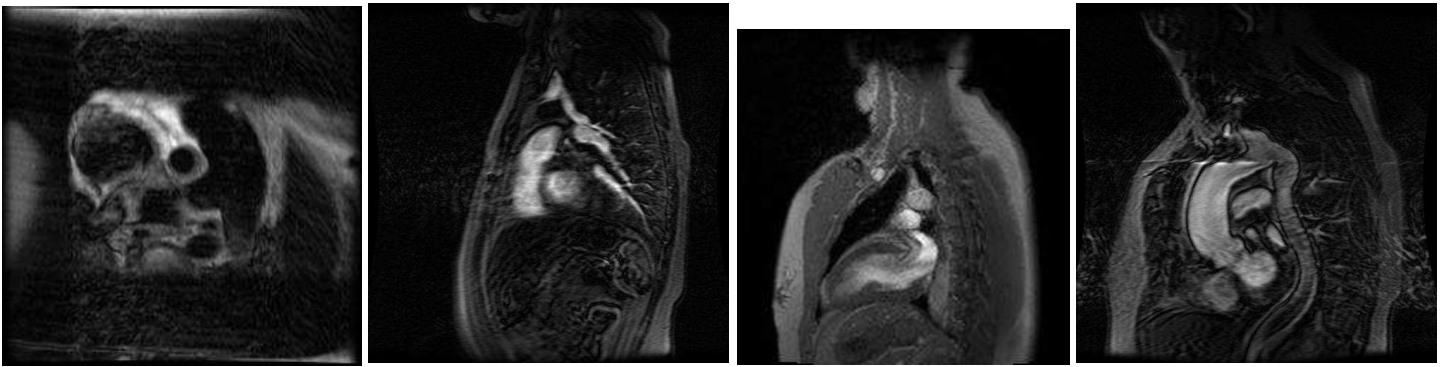
- terms:

coronary,artery,aorta,aortic,calcification,cardiac,calcium,arch,descending,vessel,heart,small,main,was,lad,mild,plaque,score,narrowing,valve,findings,causing,normal,atherosclerotic,without,arteries,protocol,contrast,calcified,moderate,rca,significant,lcx,diameter,anterior,atherosclerosis,using,proximal,this,caliber,ascending,wall,structure,root,per,non-calcified,technique,calcifications,size,agatston

- images:







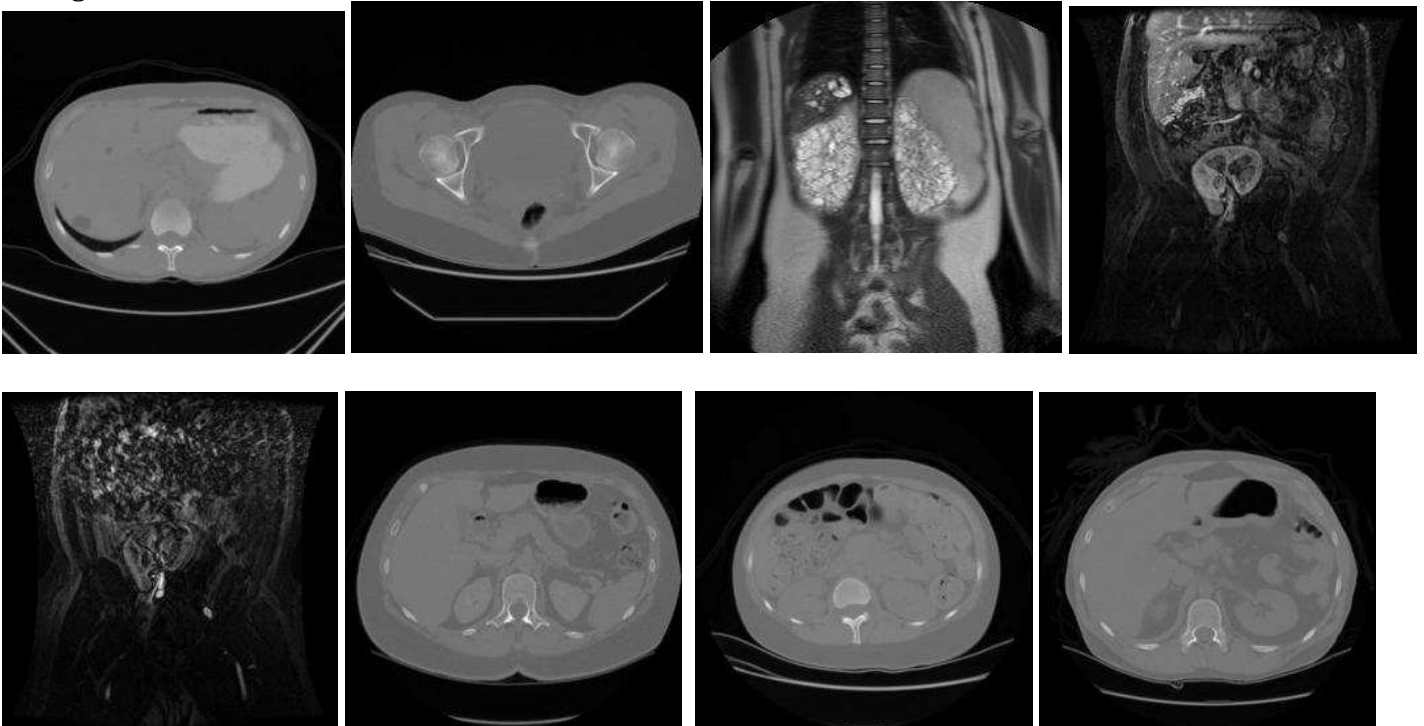
### Topic 19:

- Renal disease, mixed imaging modalities. 3.

- terms:

kidney, normal, kidneys, measures, renal, dimension, hydronephrosis, impression, ultrasound, seen, pole, craniocaudal, cyst, lesions, lam, solid, transplant, cystic, both, evidence, appear, echogenic, echogenicity, spleen, patient, stones, system, medullary, present, lower, small, upper, craniocaudal, collecting, flow, size, increased, vein, calculus, nephrocalcinosis, length, pyramids, stone, cysts, about, diameter, shows, previous, mid, appears

- images:



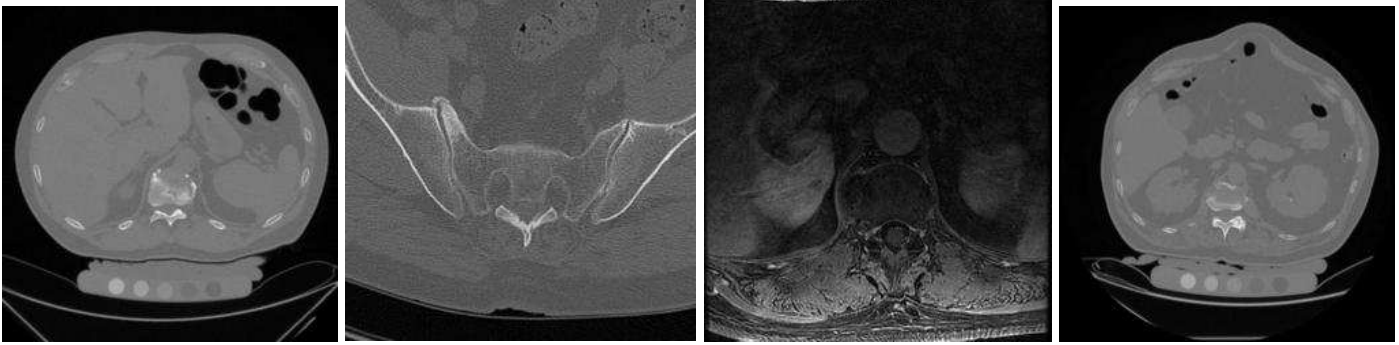
### Topic 20:

- Spine degenerative disease. 3.

- terms:

spine, degenerative, changes, narrowing, cervical, lumbar, lateral, mild, space, disc, disk, normal, joints, thoracic, minimal, evidence, joint, calcification, moderate, facet, pelvis, disease, findings, lumbosacral, views, loss, spaces, osteophytes, lower, hypertrophic, bilateral, sacroiliac, view, severe, anterior, diffuse, impression, spondylolisthesis, spondylosis, l5-s1, levels, bony, osteopenia, hips, sclerosis, alkaptonuria, history, hypertrophy, subluxation, osteophyte

- images:



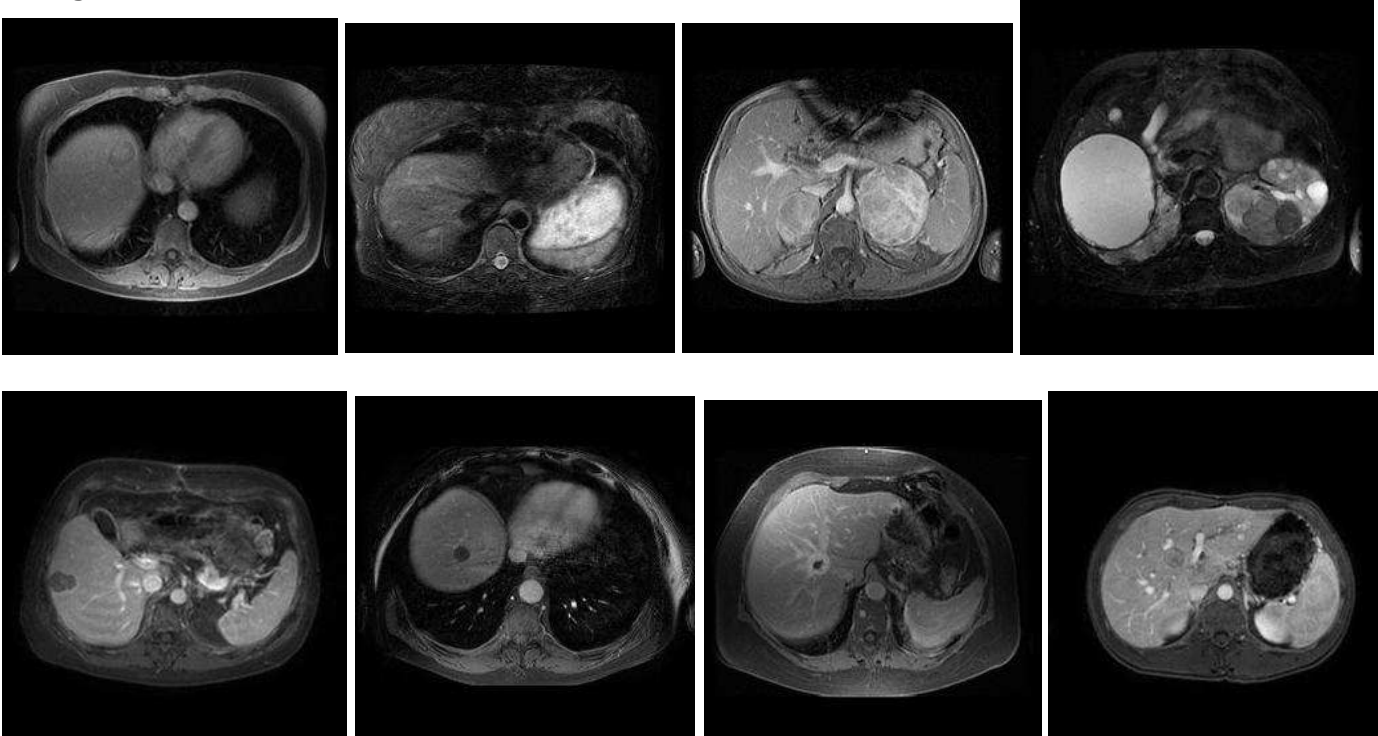
## Topic 21:

- Metastatic liver disease. 2. [Primary tumors which metastasize to liver (melanoma, lung) with numerous liver terms.]

- terms:

image, series, nodule, lobe, lesion, nodules, liver, seen, size, lesions, prior, small, lower, example, multiple, measuring, hepatic, one, anterior, posterior, enhancing, from, approximately, segment, mass, two, adjacent, these, images, larger, smaller, largest, inferior, best, see, metastases, measures, tiny, also, above, aspect, masses, diameter, increase, other, increased, dome, lung, melanoma, which

- images:



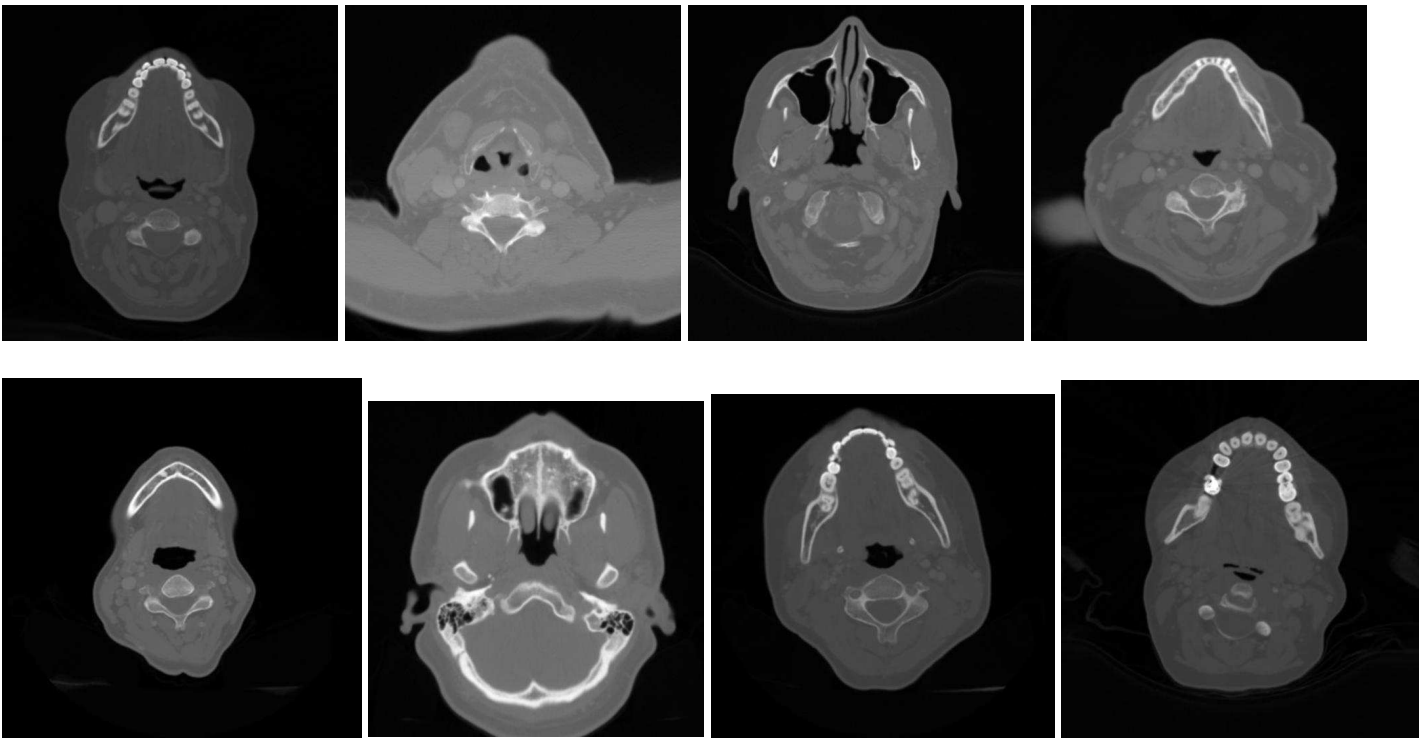
## Topic 22:

- Neck CT. 3.

- terms:

neck, unremarkable, thyroid, soft, glands, lymphadenopathy, portions, gland, submandibular, parotid, cervical, lymph, contrast, tissue, mass, tissues, visualized, findings, technique, axial, nodes, clear, airway, level, identified, enlarged, mediastinum, scan, base, included, from, impression, performed, pathologic, administration, node, 2.5, masses, side, sinuses, mandible, upper, salivary, intravenous, larynx, mastoid, jugular, paranasal, patent, mouth

- images:



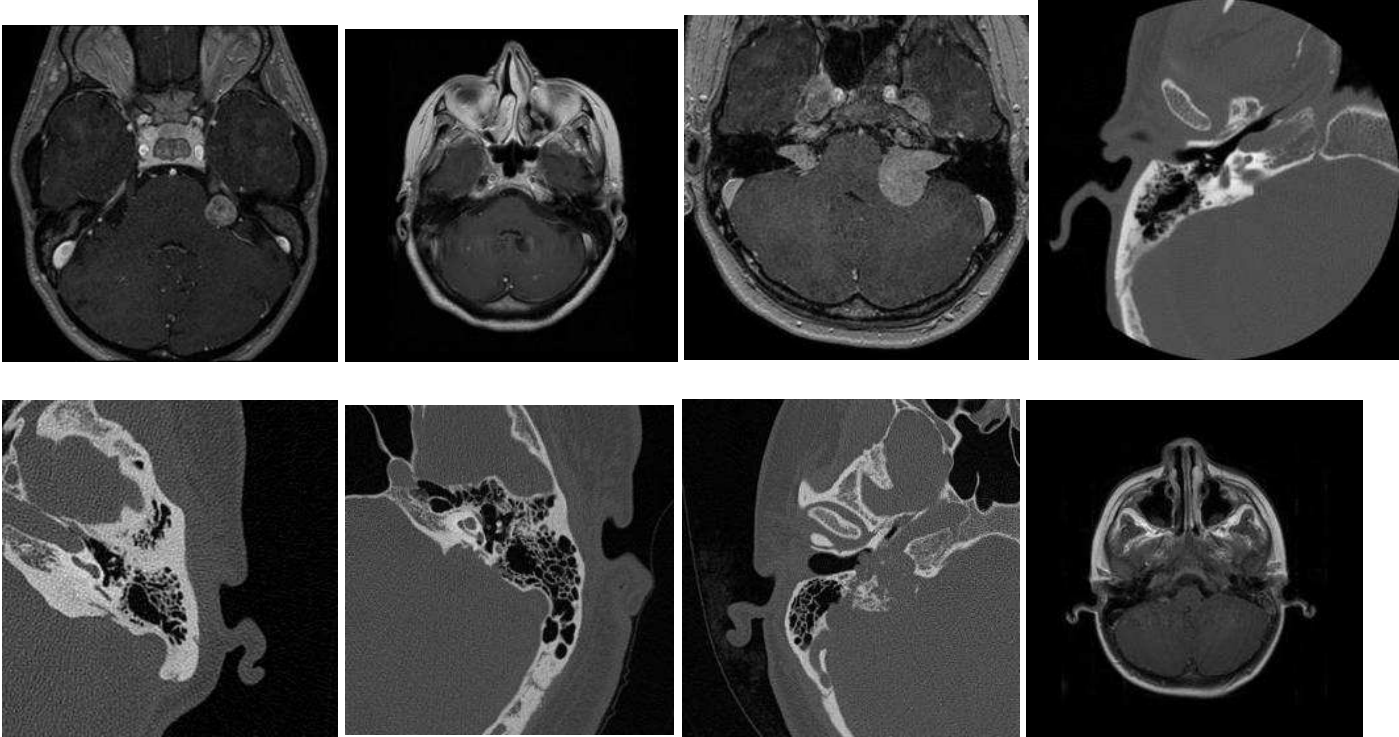
**Topic 23:**

- Inner ear neoplasm. 3.

- terms:

internal,axial,auditory,normal,flair,abnormal,canal,ear,present,inner,mri,cerebellar,middle,temporal,brain,canals,cranial,technique,fluid,meningioma,expected,findings,indication,vestibular,enhancement,lesions,bone,configuration,nor,extra-axial,contents,images,performed,mass,impression,ears,angle,endolymphatic,structures,schwannoma,petrous,folia,postcontrast,bilaterally,collections,iac,hemorrhage,obtained,cochlea,schwannomas

- images:



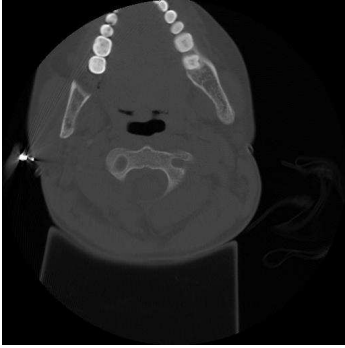
## Topic 24:

- Advanced degenerative spine disease. 3. [Terms to suggest advanced stage (fracture, compression, deformity, multiple, osteopenia, kyphosis).]

- terms:

spine,vertebral,thoracic,scoliosis,rib,lumbar,body,fracture,lateral,compression,bodies,fractures,thoracolumbar,ribs,deformity,anterior,evidence,lower,findings,multiple,upper,vertebrae,mild,history,from,vertebra,healed,height,t12,degrees,mid,osteopenia,column,kyphosis,curvature,loss,about,view,posterior,anomaly,healing,minimal,deformities,series,views,t11,fusion,convexity,anomalies,convex

- images:



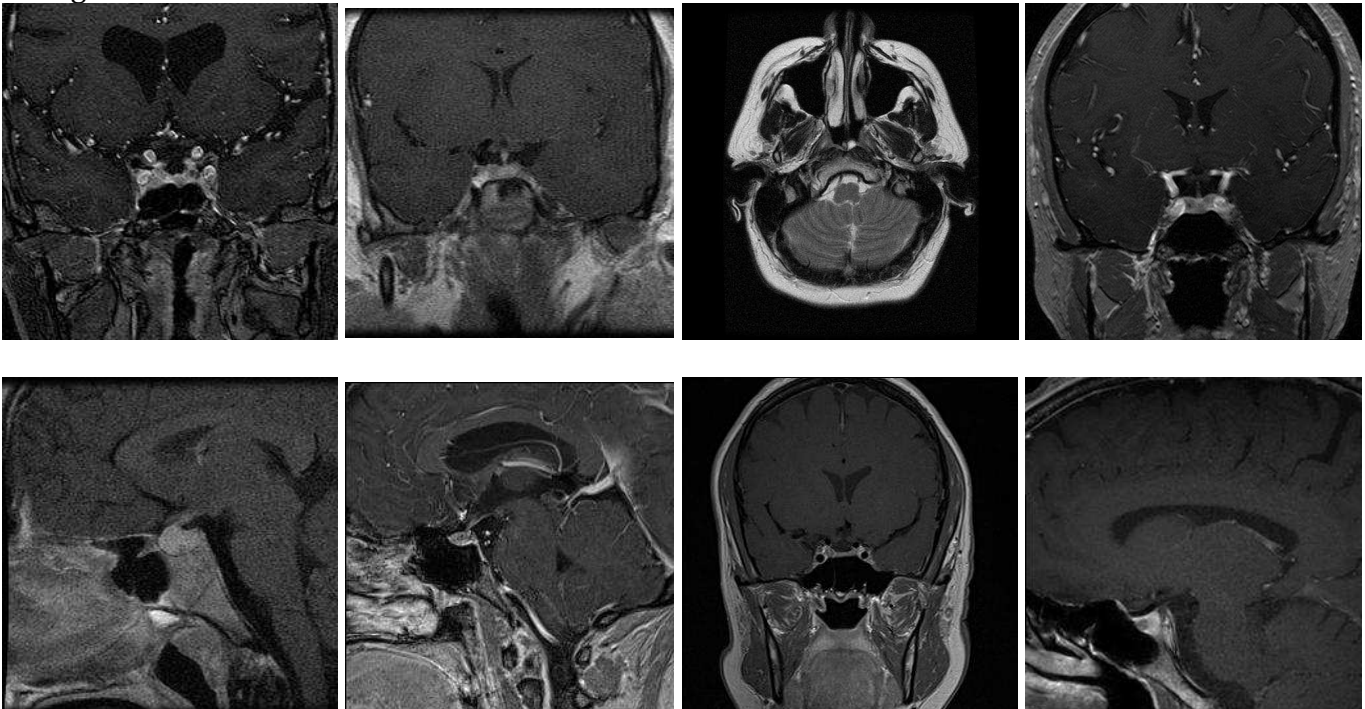
## Topic 25:

- Anterior skull base neoplasm. 3.

- terms:

pituitary,optic,gland,coronal,sagittal,enhancement,postcontrast,cavernous,sella,normal,contrast,chiasm,adenoma,nerve,suprasellar,orbit,sinus,mri,nerves,orbits,t1-weighted,cushing,technique,lesion,within,findings,unremarkable,impression,size,stalk,syndrome,pre,ectopic,history,brain,post,mass,this,infundibulum,fat,magnevist,globe,sphenoid,side,post-contrast,region,portions,midline,homogeneously,evidence

- images:



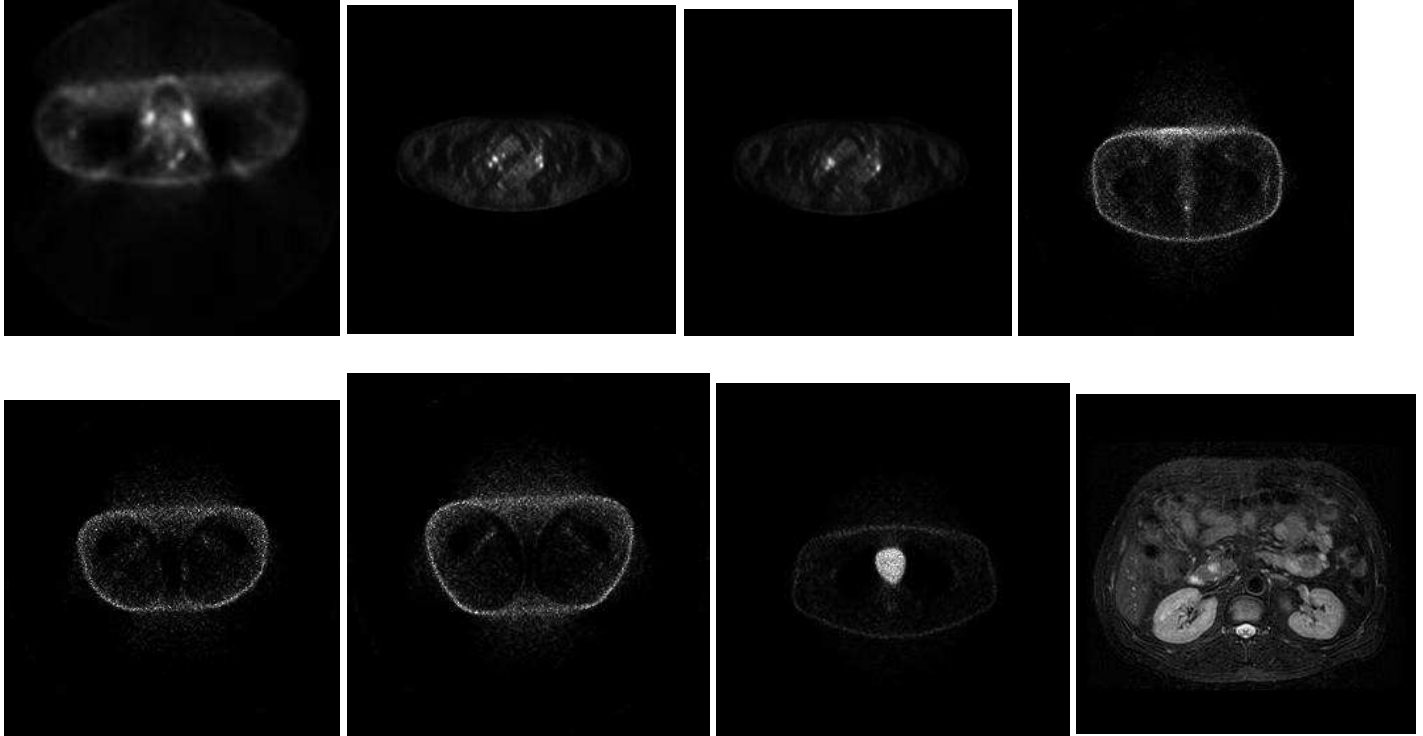
## Topic 26:

- PET. 2. [Terms refer predominantly refer to PET (uptake, FDG, PET, foci, SUV, dL, minutes).]

- terms:

uptake, patient, was, scan, seen, increased, this, that, injection, fdg, imaged, note, not, focus, from, had, mild, upper, pet, performed, foci, previous, starting, also, please, suv, diagnostic, only, prior, mg/dl, attenuation, following, does, above, small, quality, head, region, mci, areas, correction, purposes, before, minutes, arms, area, approximately, abnormal, used, maximum

- images:



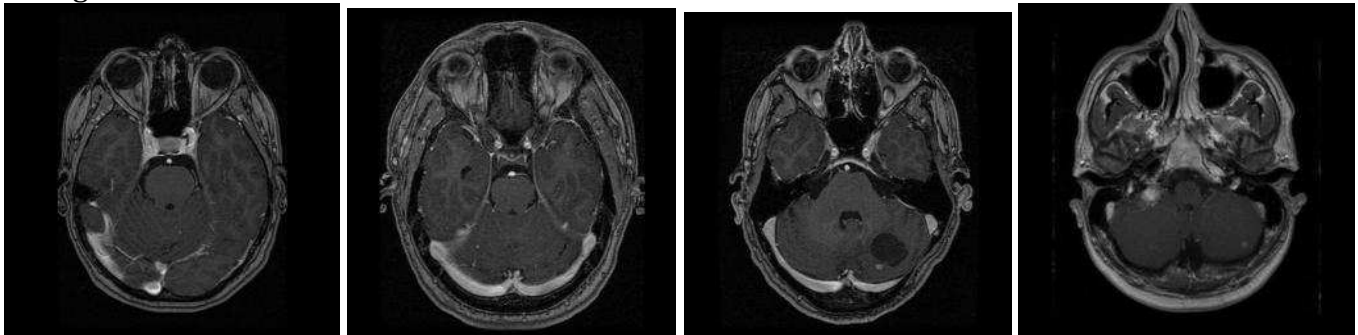
## Topic 27:

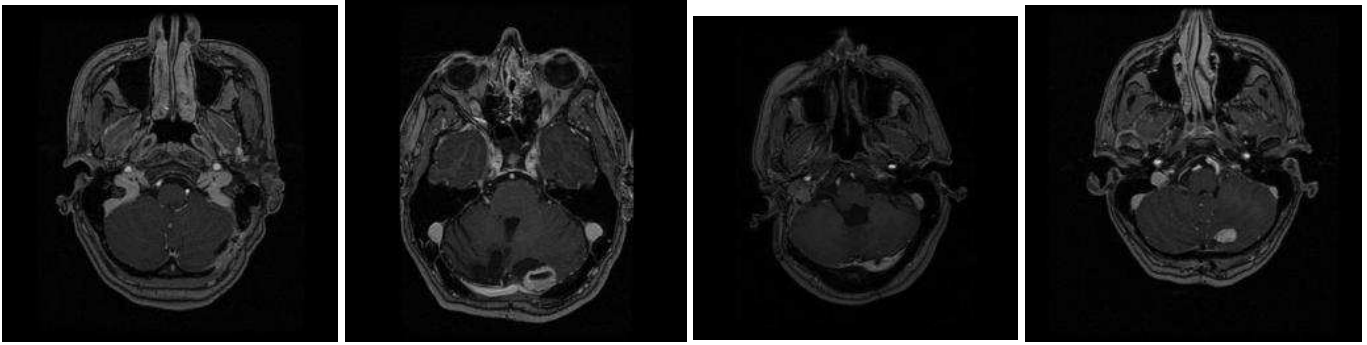
- Cerebellar neoplasm. 3.

- terms:

posterior, fossa, enhancing, edema, cerebellar, lesion, brain, ventricle, small, hemangioblastoma, hemangioblastomas, hemisphere, lateral, cerebellum, associated, axial, cyst, aspect, fourth, vhl, this, post, size, von, supratentorial, tumor, effect, evidence, shunt, punctate, identified, lesions, enhancement, contrast, mri, hippel-lindau, sac, postoperative, cystic, findings, craniectomy, suboccipital, postcontrast, technique, endolymphatic, a long, pre, these, third, occipital

- images:





**Topic 28:**

- DEXA. 3.

- terms:

body,fat,total,whole,region,composition,bmd,bone,includes,bmc,used,lean,was,head,mass,subtotal,grams,mineral,~grams,patient,were,measured,weight,height,values,age,compares,dual,average,following,content,determine,obtained,instrument,absorptiometry,z-score,energy,entire,t-

score,excluding,date,number,'92s,

accession,impression,men,women,postmenopausal,time,same

- images:

NO IMAGES AVAILABLE

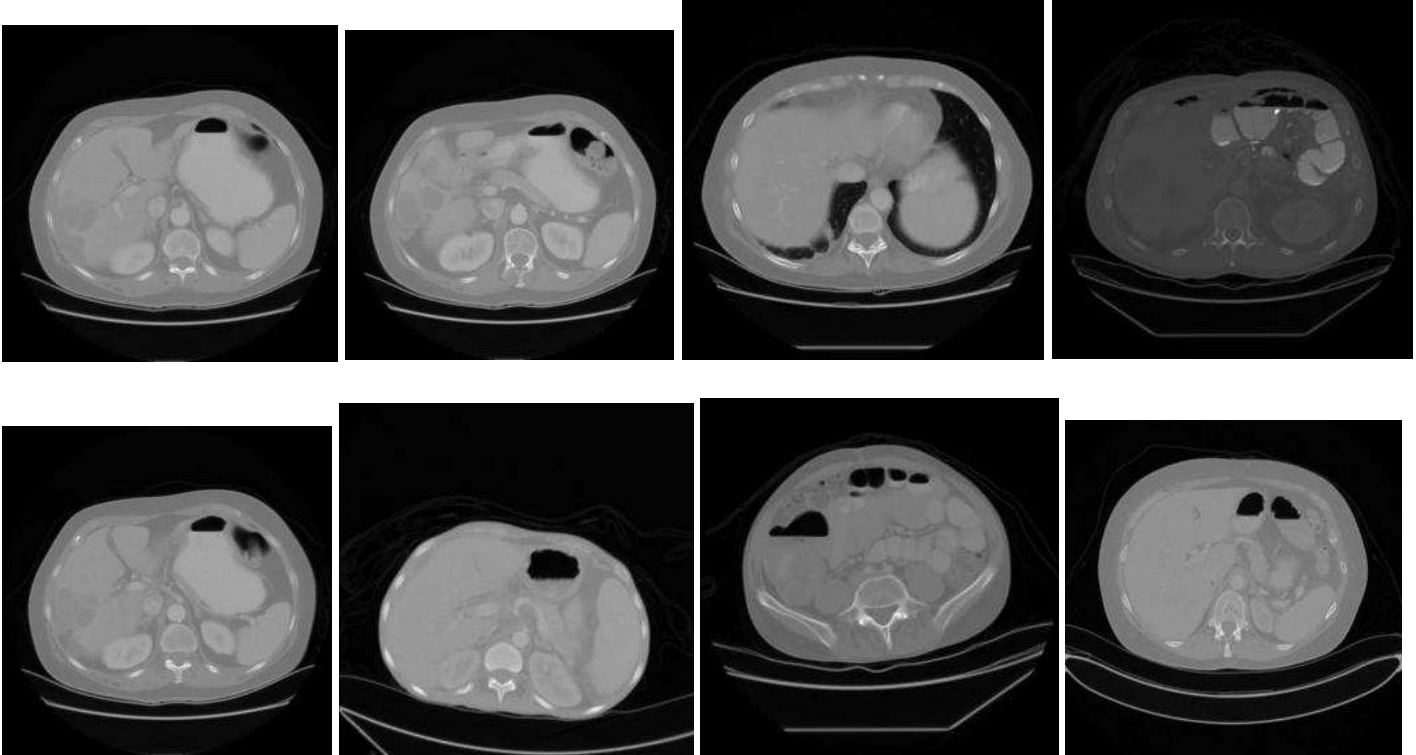
**Topic 29:**

- Gastrointestinal tract disease. 3.

- terms:

bowel,abdomen,colon,small,air,abdominal,quadrant,fluid,upper,contrast,obstruction,gas,wall,pelvis,loops,stomach,free,evidence,distal,lower,peritoneal,amount,material,gastric,pattern,ascites,distention,dilated,findings,large,thickening,clips,esophagus,surgical,upright,distended,impression,seen,proximal,nonspecific,supine,rectum,duodenum,multiple,sigmoid,filled,barium,hernia,loop,dilatation

- images:



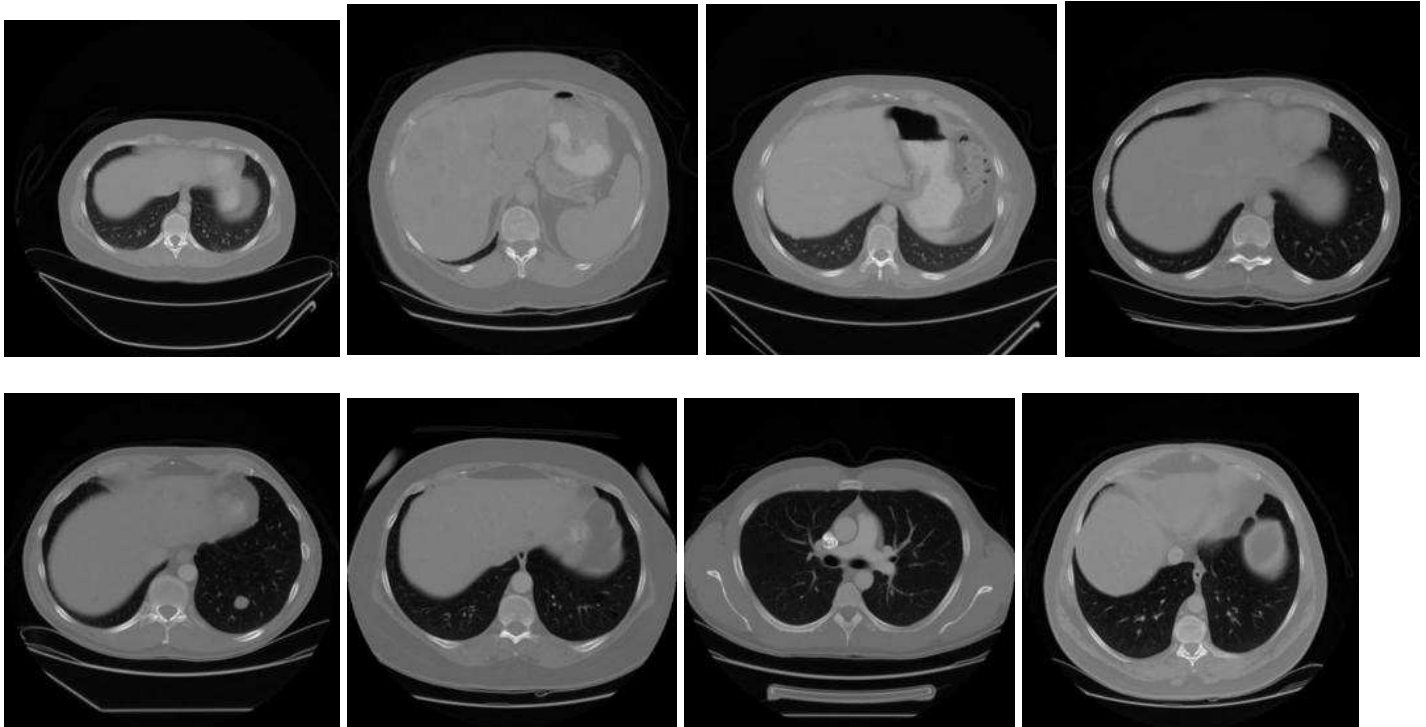
### Topic 30:

- Metastatic disease. 2. (masses, adenopathy, nodules)

- terms:

abdomen, pelvis, chest, contrast, performed, oral, was, present, masses, stable, intravenous, adenopathy, liver, retroperitoneal, comparison, administration, scans, 130, small, parenchymal, mediastinal, dated, after, which, evidence, were, pulmonary, made, adrenal, prior, pelvic, without, cysts, spleen, mass, disease, multiple, isovue-300, obtained, areas, consistent, nodules, changes, pleural, lesions, following, abdominal, that, hilar, axillary

- images:



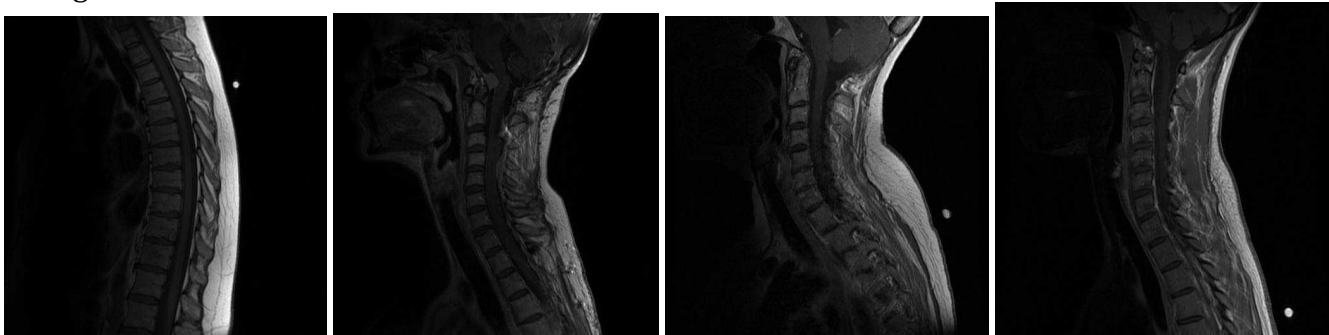
### Topic 31:

- Degenerative disc disease (spine). 3.

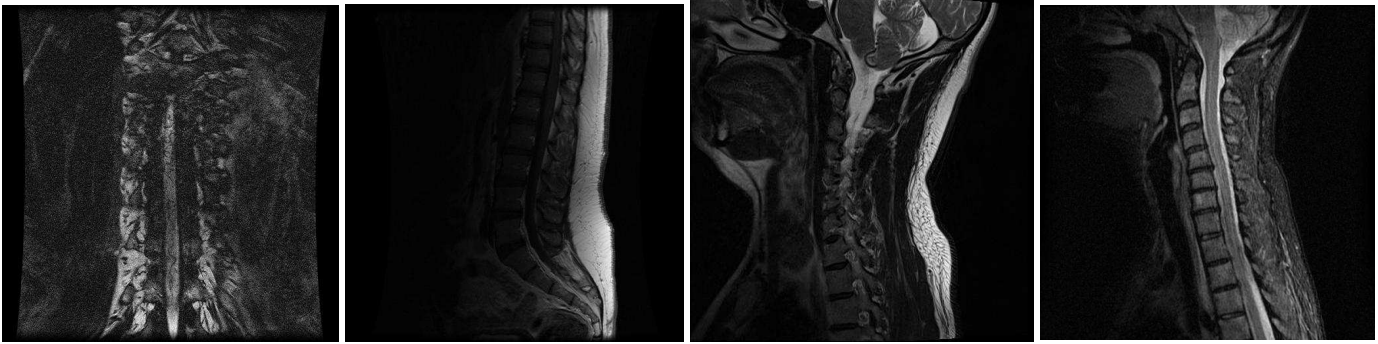- terms:

spine, cord, cervical, thoracic, spinal, level, canal, lumbar, sagittal, vertebral, neural, disc, signal, mri, body, technique, levels, findings, foramina, mild, disk, nerve, within, small, marrow, central, bodies, normal, impression, enhancing, conus, syrinx, this, narrowing, lesions, roots, contrast, throughout, bone, degenerative, foramen, protrusion, multiple, l5-s1, also, abnormal, c5-c6, posterior, changes, heights

- images:







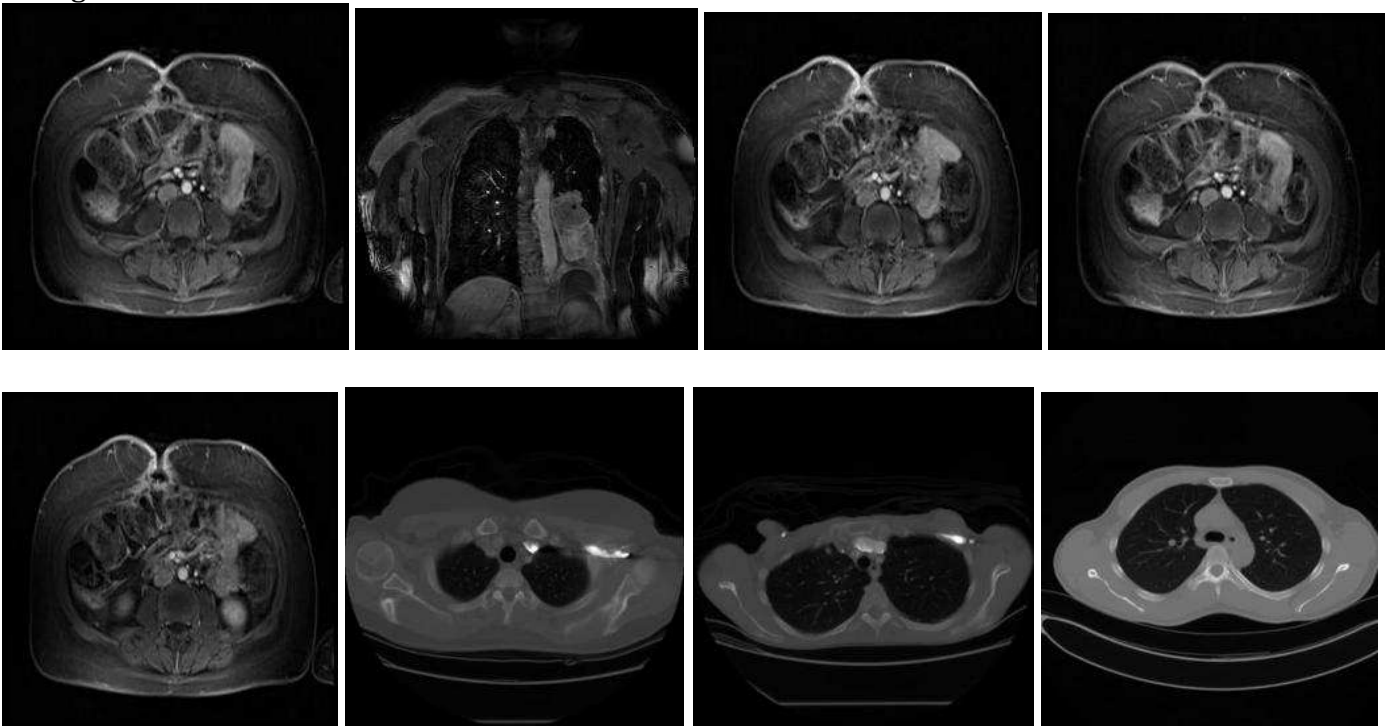
### Topic 32:

- Full body screening of diffuse disease. 1. (screen\*, syndrome, hodgkins, unknown)

- terms:

clinical,reason,information,comparison,findings,impression,examination,protocol,2009,2008,none,melanoma,r/o,2007,syndrome,per,please,screening,evaluate,followup,f/u,2010,s/p,disease,patient,h/o,eval,lat,screen,needs,evaluation,given,baseline,dependence,alcohol,ocular,hyper,hcl,y/o,job,hodgkins,consult,assess,ige,routine,need,part,visit,here,unknown

- images:



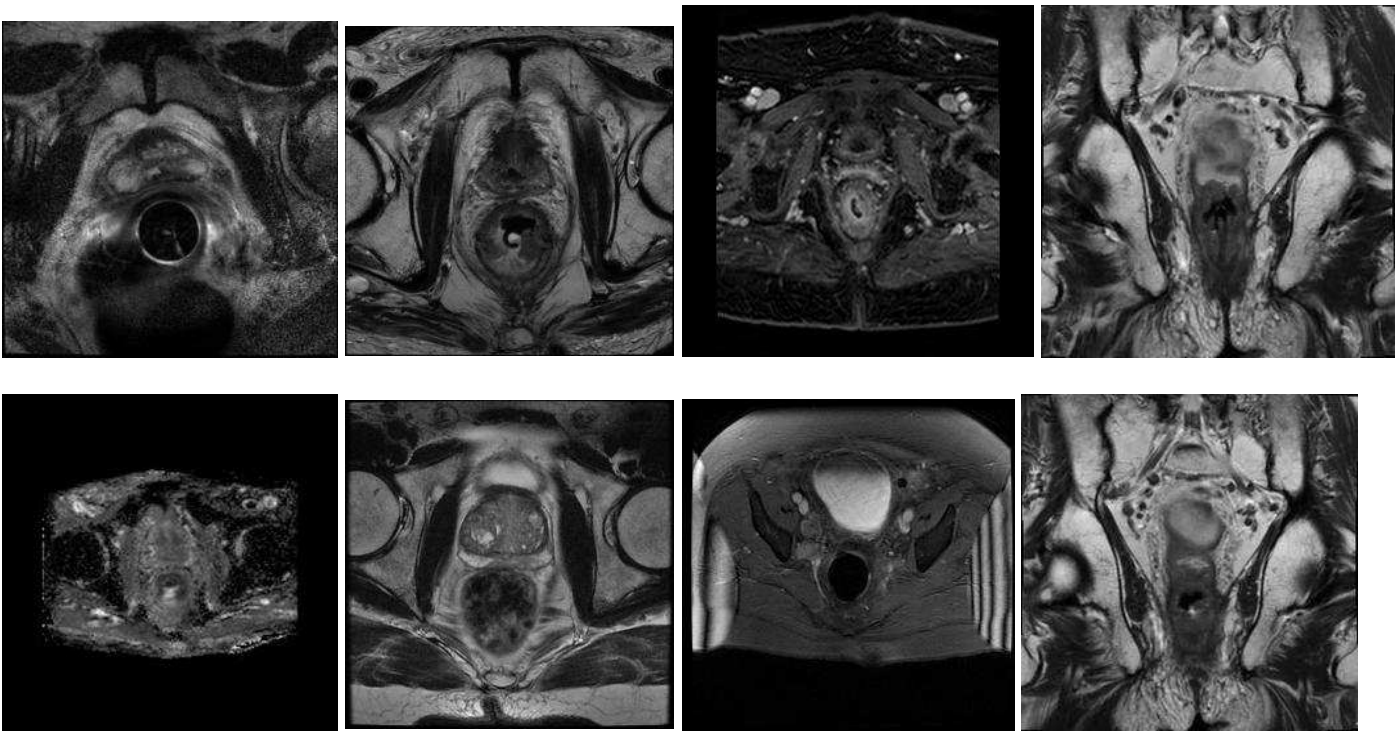
### Topic 33:

- Prostate MRI. 3.

- terms:

mri,lesion,prostate,peripheral,zone,gland,obtained,were,this,positive,has,coil,mid,weighted,spectroscopy,seminal,present,dce,adc,volume,low,disease,images,central,scans,diffusion,vesicles,bony,maps,ece,t1-weighted,normal,nodal,image,lesions,cancer,bladder,axial,greatest,which,apical,residual,demonstrates,anterior,was,t2w,urine,dimension,t2-weighted,using

- images:



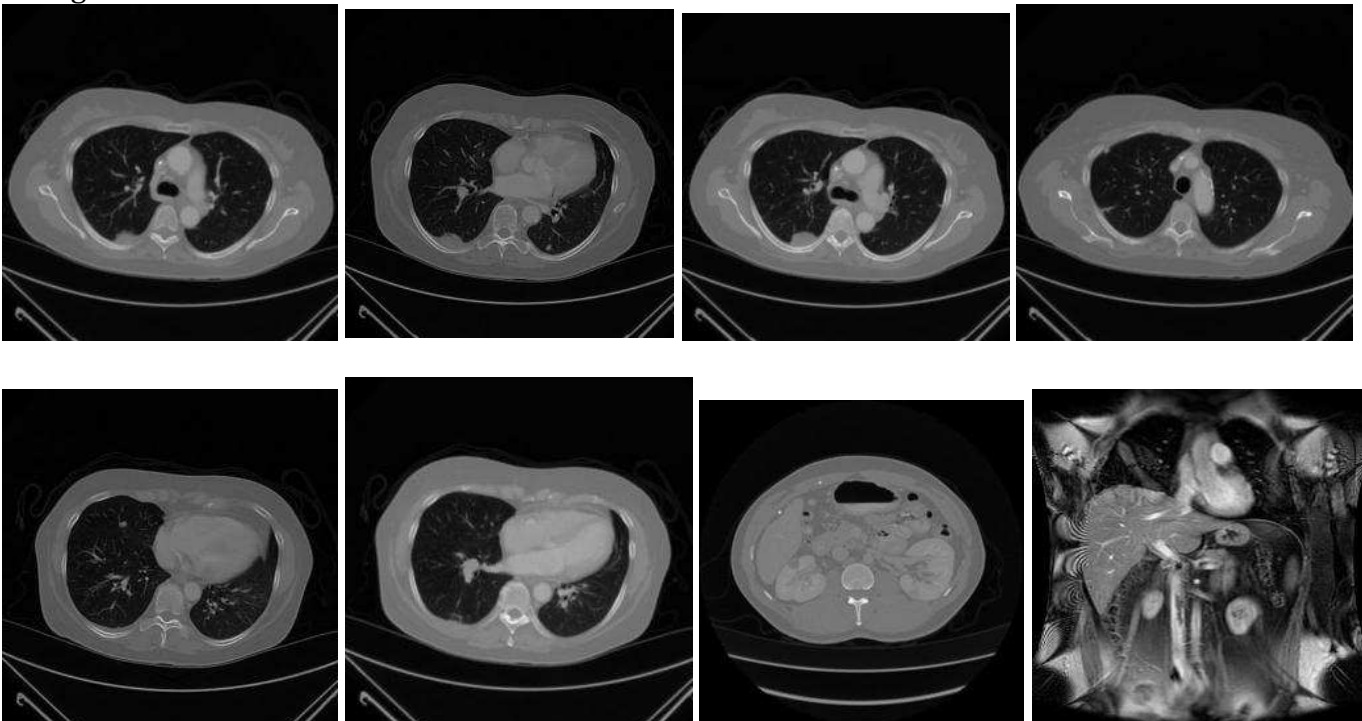
### Topic 34:

- Central venous catheter placement. 3. [The images are from CTs, however this words in this word cluster are more strongly associated with radiographs.]

- terms:

tip, catheter, line, vena, cava, superior, venous, central, picc, atrium, chest, junction, svc, its, position, insertion, placement, single, level, findings, view, subclavian, jugular, pneumothorax, verify, post-picc, over, upper, entering, port-a-cath, from, vein, right-sided, left-sided, region, near, radiograph, enters, frontal, impression, other, evidence, repositioning, internal, mediastinal, contours, demonstrates, post, placed, place

- images:



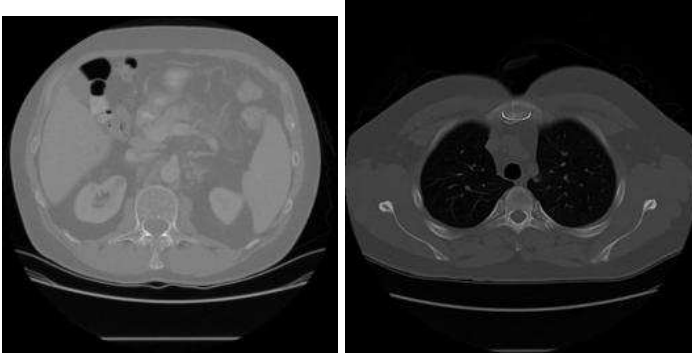
### Topic 35:

- CT performed to detect interval change, most likely in the postoperative period. 2.

- terms:

stable, unchanged, change, since, interval, significant, again, impression, compared, prior, changes, findings, comparison, appearance, remains, new, remain, without, examination, abnormal, bilateral, postsurgical, dated, postoperative, follow, developing, from, essentially, otherwise, follow-up, other, likely, mild, differences, when, technique, previously, diffuse, overall, minimally, probably, persistent, including, throughout, seen, scattered, bilaterally, allowing, surgical, redemonstration

- images:



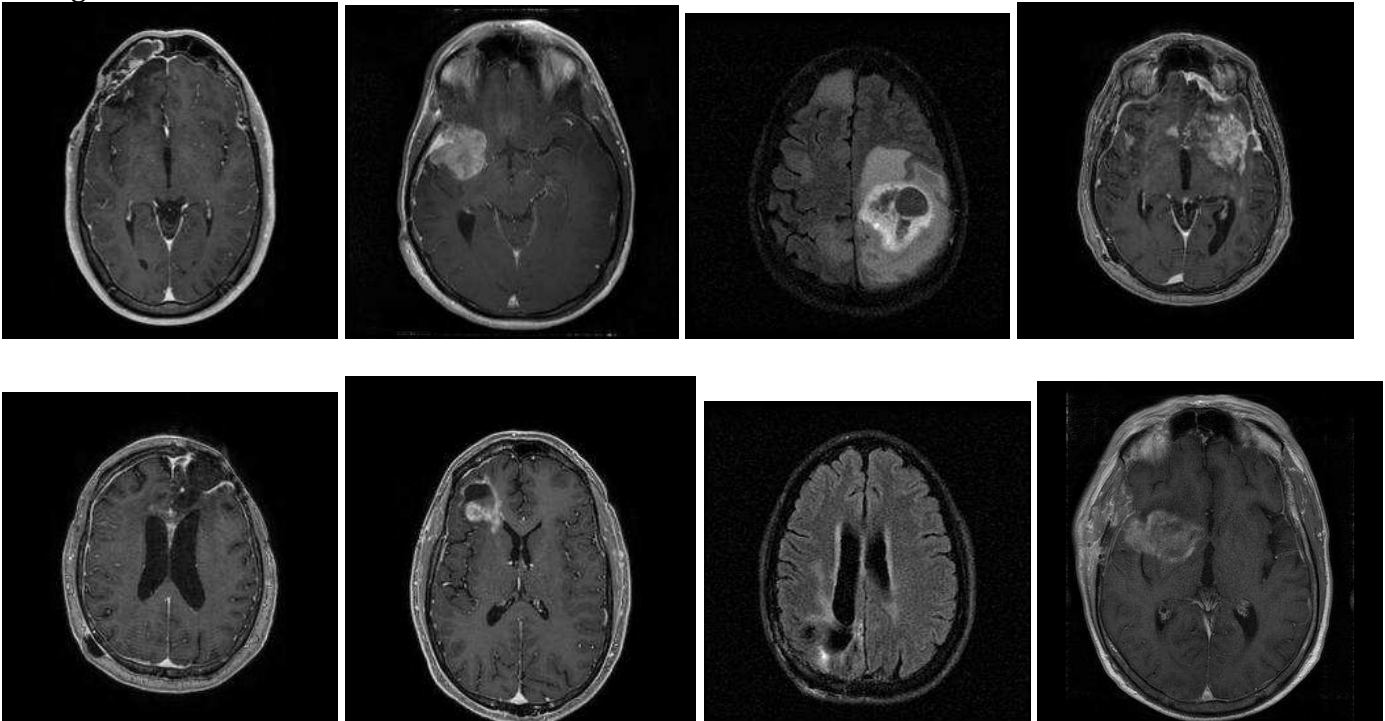
### Topic 36:

- Brain tumor. 3.

- terms:

lobe, frontal, cavity, tumor, enhancement, perfusion, temporal, blood, increased, postoperative, signal, cerebral, parietal, abnormal, surgical, volume, out, adjacent, scan, this, brain, rule, lateral, gradient, echo, also, enhancing, within, changes, performed, ventricle, progression, high, white, surrounding, matter, lesion, mass, lobes, hemisphere, basal, mri, postcontrast, infiltrative, occipital, areas, imaging, corpus, hemorrhage, ganglia

- images:



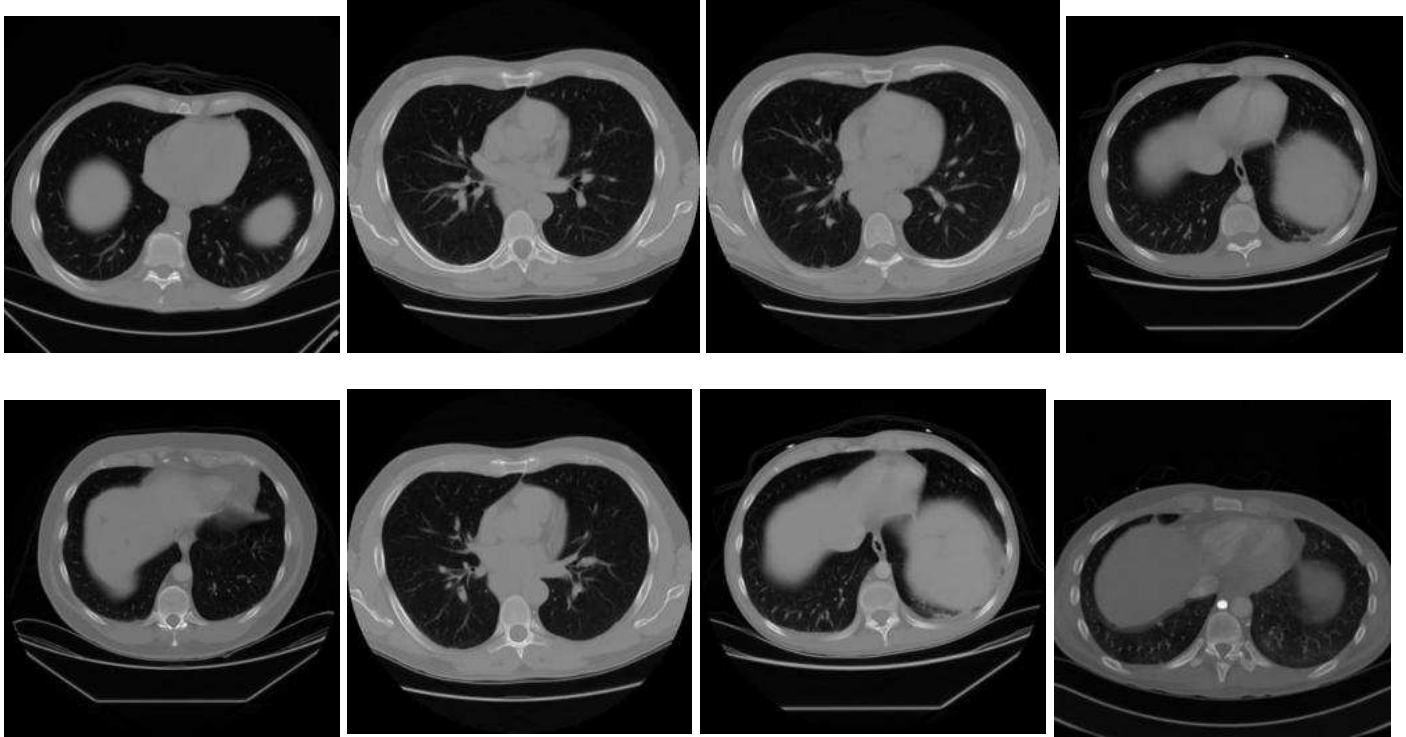
### Topic 37:

- CT performed to acute respiratory symptoms in the setting of a chronic disease. 2. [There are several words indicative of acute respiratory symptoms (pain, infection, now, acute, cough, onset, edema, fever) in the backround of multiple different diseases which are unrelated to one another (sickle, lymphoma, transplant, aplastic, cgd).]

- terms:

out,rule,history,cell,pain,lymphoma,findings,transplant,disease,new,fever,please,impression,infection,evidence,male,patient,anemia,post,s/p,sickle,now,acute,chronic,old,reason,female,year,hiv,cough,y/o,onset,evaluate,aplastic,recent,stem,leukemia,abscess,pneumonia,r/o,neutropenic,severe,diffuse,h/o,ago,comparison,cgd,edema,days,fevers

- images:



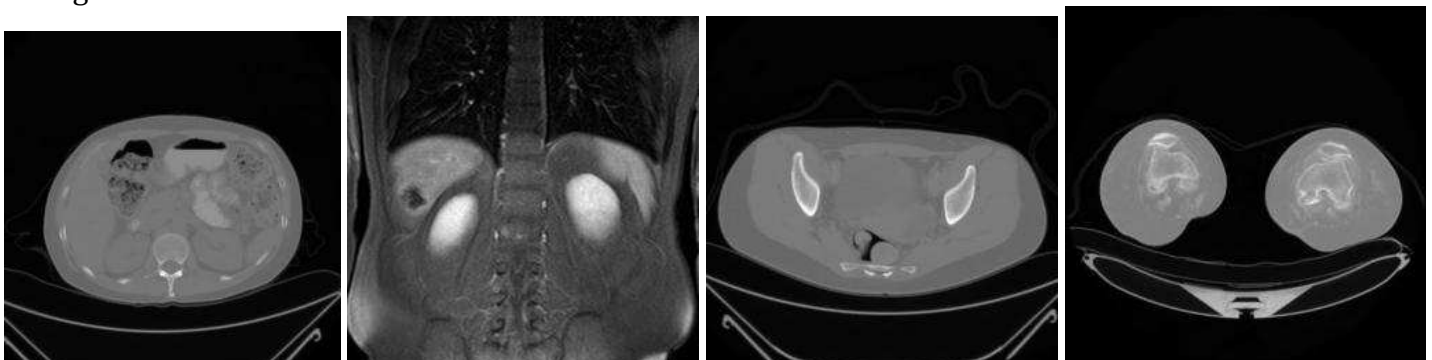
### Topic 38:

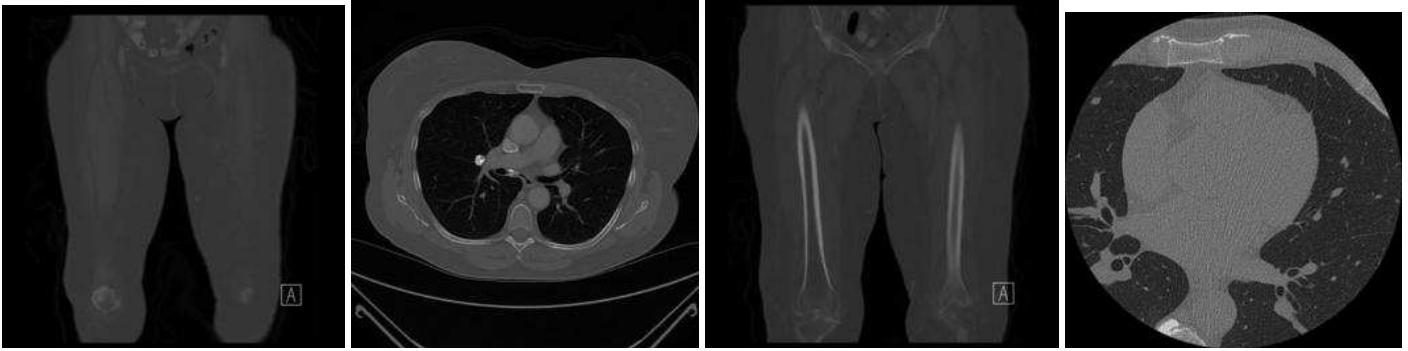
- Report headers. 3. [These are terms that appear in almost all reports as headers. It is unclear to me why this became a separate category, and how these specific images became linked with this category.]

- terms:

exam,into,entered,clinician,cris,ordering,reason,mrn,findings,comparison,impression,2011,2012,2013,protocol,none,2010,`s,evidence,please,r/o,normal,patient,technique,evaluate,s/p,per,baseline,f/u,eval,restaging,bilateral,h/o,evaluation,july,june,screening,august,visit,september,april,october,non,need,assess,screen,november,march,??s,february

- images:





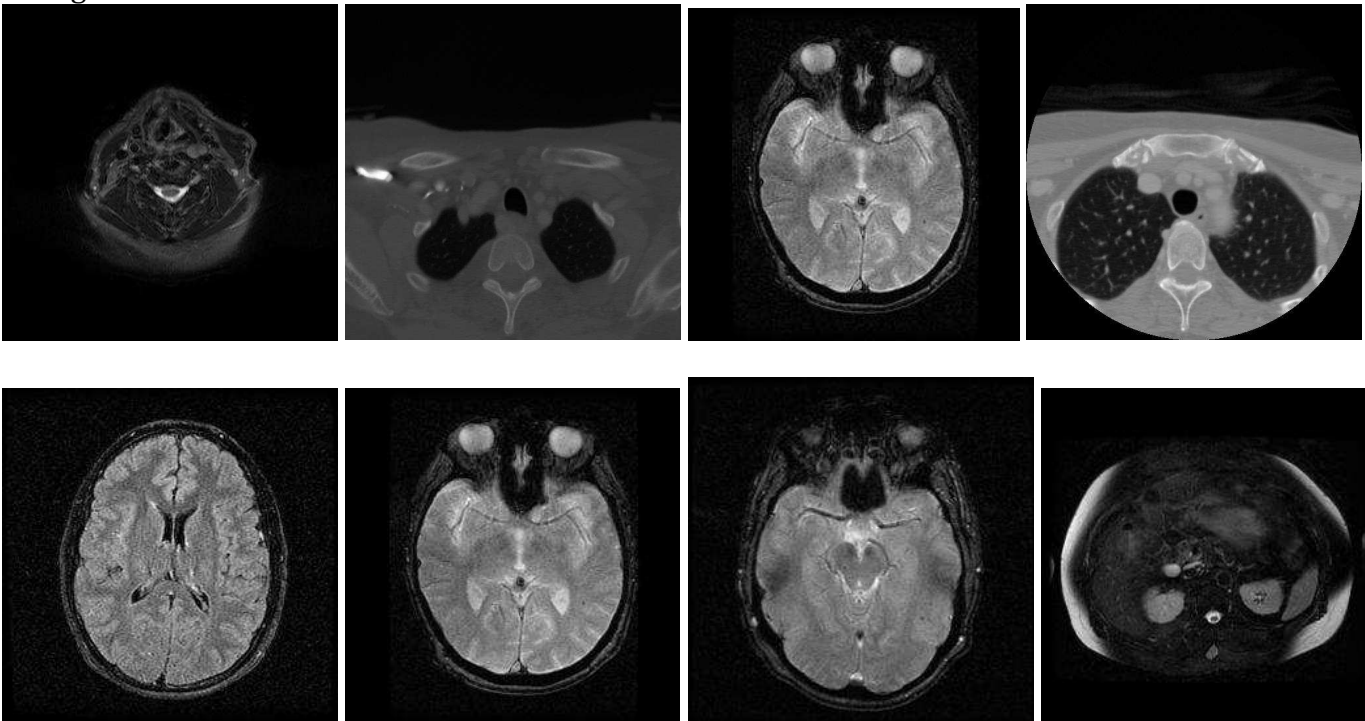
### Topic 39:

- MRA of neck. 2. [Most terms/images refer to neck MRA, but several thyroid terms are also included which may have been described as incidental findings in a neck MR.]

- terms:

thyroid, artery, carotid, arteries, internal, parathyroid, mra, stenosis, lobe, posterior, vascular, segment, normal, cerebral, impression, anterior, vertebral, gland, circle, willis, angiography, vessels, proximal, middle, distal, evidence, adenoma, circulation, aneurysm, time, angiogram, both, goiter, neck, isthmus, bifurcation, intracranial, basilar, origin, lobes, hypoechoic, flight, hyperparathyroidism, seen, visualized, multinodular, time-of-flight, enlarged, inferior, involving

- images:



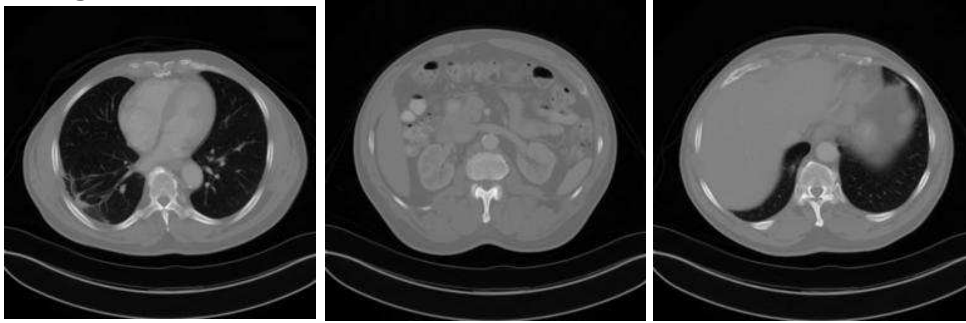
### Topic 40:

- Cardiac stress test. 3. [Unclear how CT images are related to words from a cardiac stress test.]

- terms:

was, patient, normal, rest, exercise, peak, baseline, stress, were, images, myocardial, history, mci, perfusion, imaging, heart, rate, has, motion, impression, ventricular, injection, minutes, procedure, had, size, fraction, ejection, this, during, increased, blood, ventricle, mmhg, technique, performed, pressure, findings, artifact, injected, significant, minute, thallium-201, per, wall, showed, after, total, she, beats

- images:



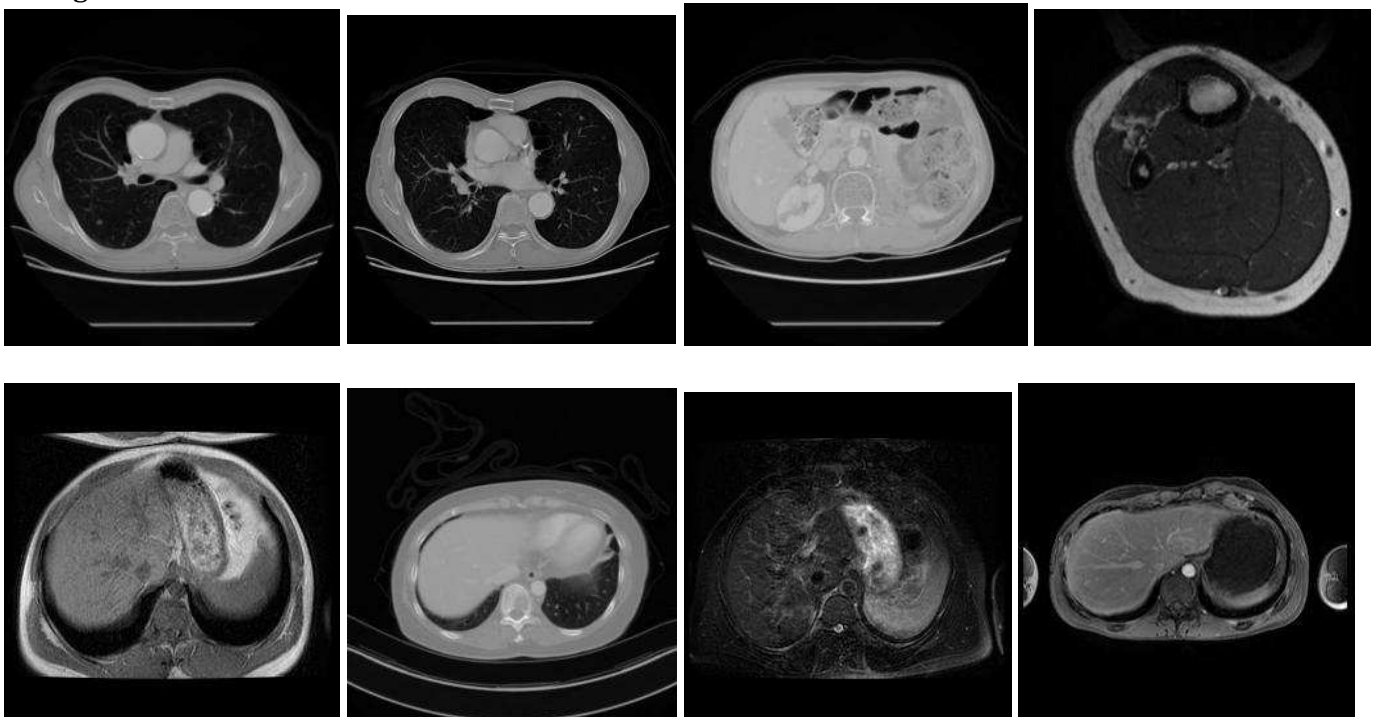
### Topic 41:

- Metastatic disease follow-up examination. 2. [There are several unrelated primary tumors mentioned (melanoma, prostate, sarcoma, renal, thyroidectomy, ewing), but many other words suggests multifocal metastatic disease (metasta\*, recurren\*, mets, multiple, masses).]

- terms:

metastatic,post,cancer,metastases,disease,history,evidence,status,metastasis,surgical,carcinoma,resection,recurrent,impression,surgery,melanoma,prostate,cell,changes,bed,residual,radiation,findings,sarcoma,patient,s/p,mets,thyroidectomy,clips,thyroid,therapy,recurrence,treatment,male,renal,operative,tumor,comparison,restaging,site,multiple,ewing,baseline,status-post,medullary,suggest,masses,postsurgical,bone,female

- images:



### Topic 42:

- Brain imaging, NOS. 2. [This cluster has a few words that specifically refer to MR (sagittal, mri, flair), but several images are CT.]

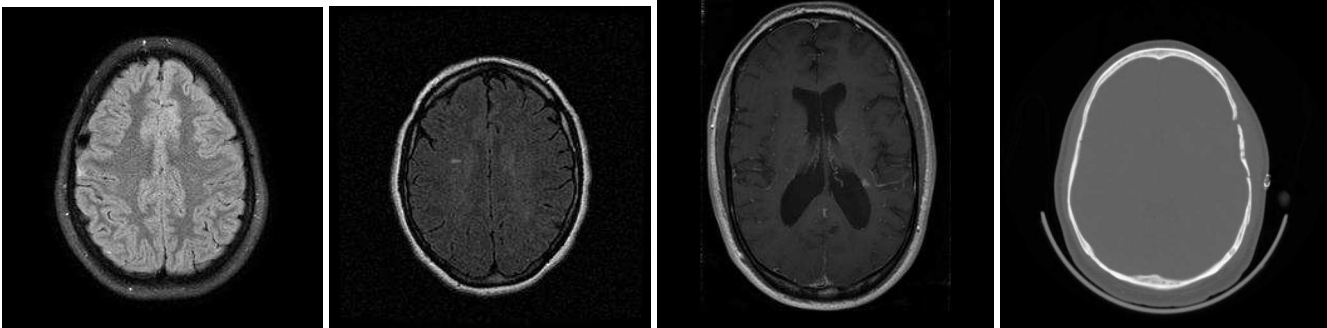
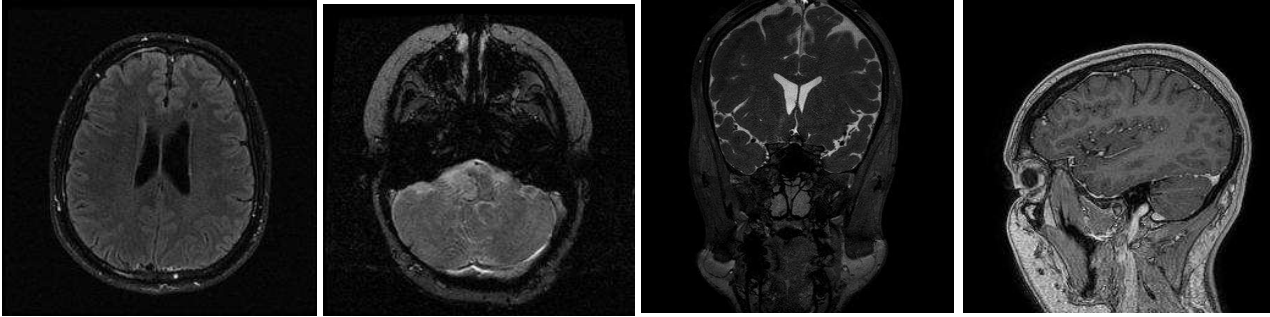
- terms:

axial,seen,brain,stable,normal,sagittal,within,hemorrhage,bilaterally,air,history,mri,performed,were,cells,mastoid,technique,midline,comparison,contrast,findings,orbits,postcontrast,globes,shift,sinuses,images,p



aranasal,well,pre,ventricles,acute,flair,intracranial,mild,mass,post,matter,pneumatized,that,impression,loss,size,differentiation,margins,gray-white,head,clinical,tissues,elevated

- images:



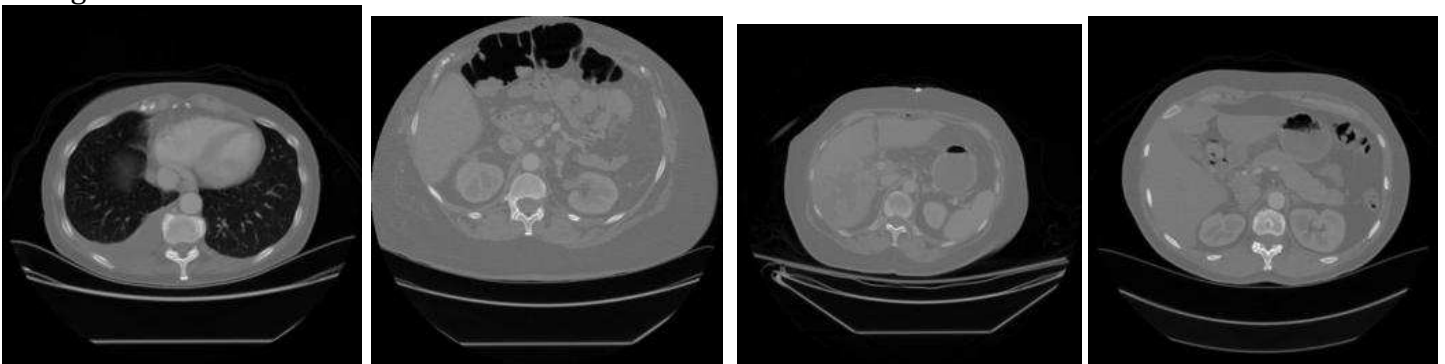
### Topic 43:

- Interventional procedure, vascular/nonvascular mixed. 3. [This cluster has vascular interventional terms (artery, sheath, femoral, infusion) and nonvascular terms (drainage).]

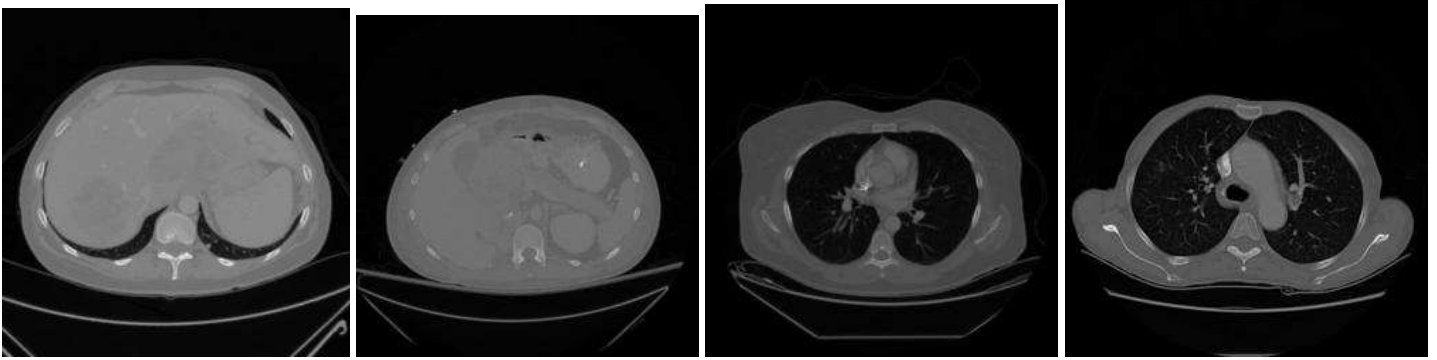
- terms:

was,artery,hepatic,patient,catheter,vein,from,into,this,performed,were,contrast,common,injection,venous,sheath,that,after,then,procedure,had,femoral,french,arterial,placed,inferior,minutes,showed,infusion,celiac,given,through,used,balloon,because,internal,jugular,following,melphalan,drainage,which,under,during,superior,advanced,well,catheters,filtration,tpa,patent

- images:







#### Topic 44:

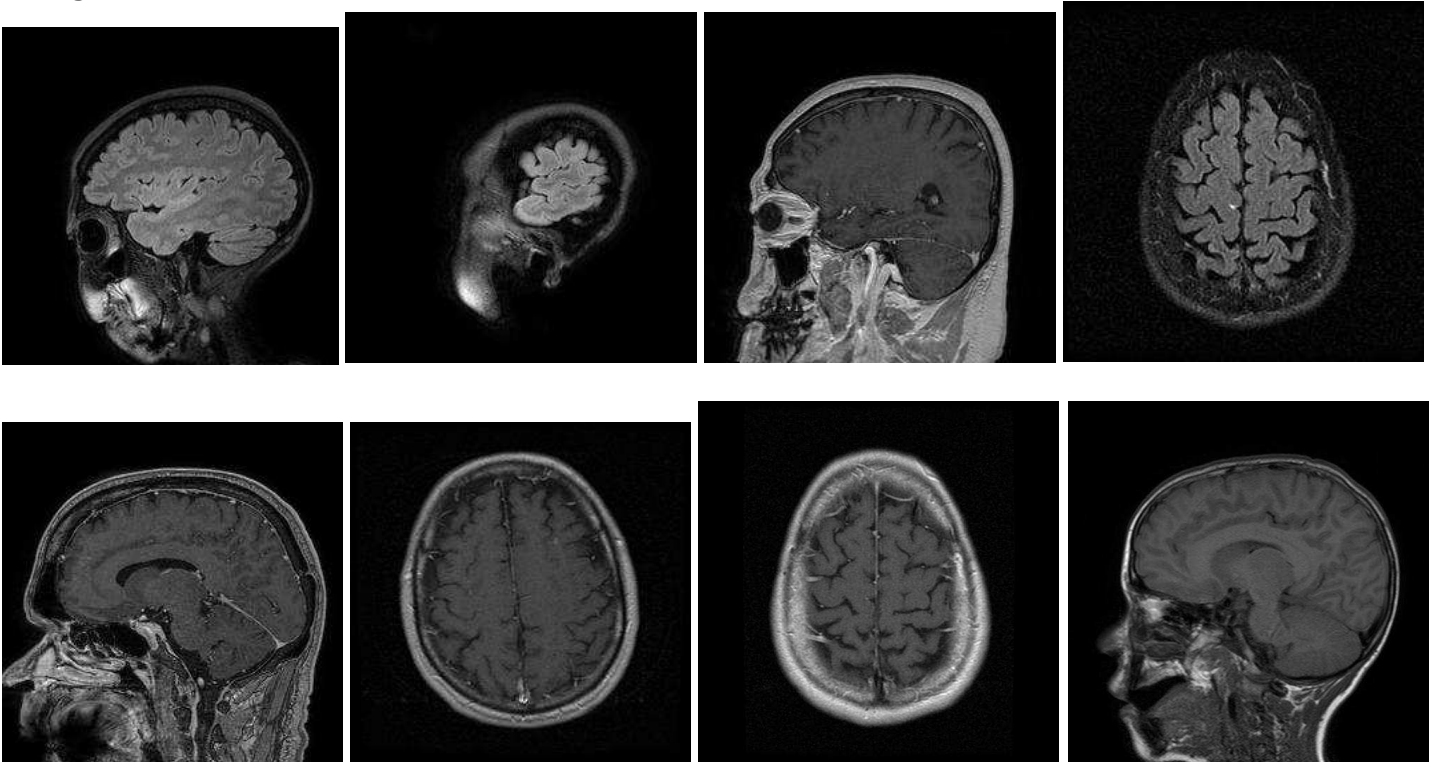
- Brain MRI, NOS. 3. [This cluster contains a few words in a normal brain MR report template (unremarkable, normal).]

- terms: axial,brain,unremarkable,images,t1-

weighted,were,clear,sagittal,administration,mri,contrast,normal,without,acquired,identified,ventricles,su  
lci,mastoid,cells,air,infarct,flair,their,matter,material,contents,t2-

weighted,mass,indication,hemorrhage,cerebellar,orbits,intravascular,not,comparison,white,technique,pa  
ranasal,age,signal,patient,within,abnormal,findings,sinuses,prominent,flow,impression,magnum,foramen

- images:



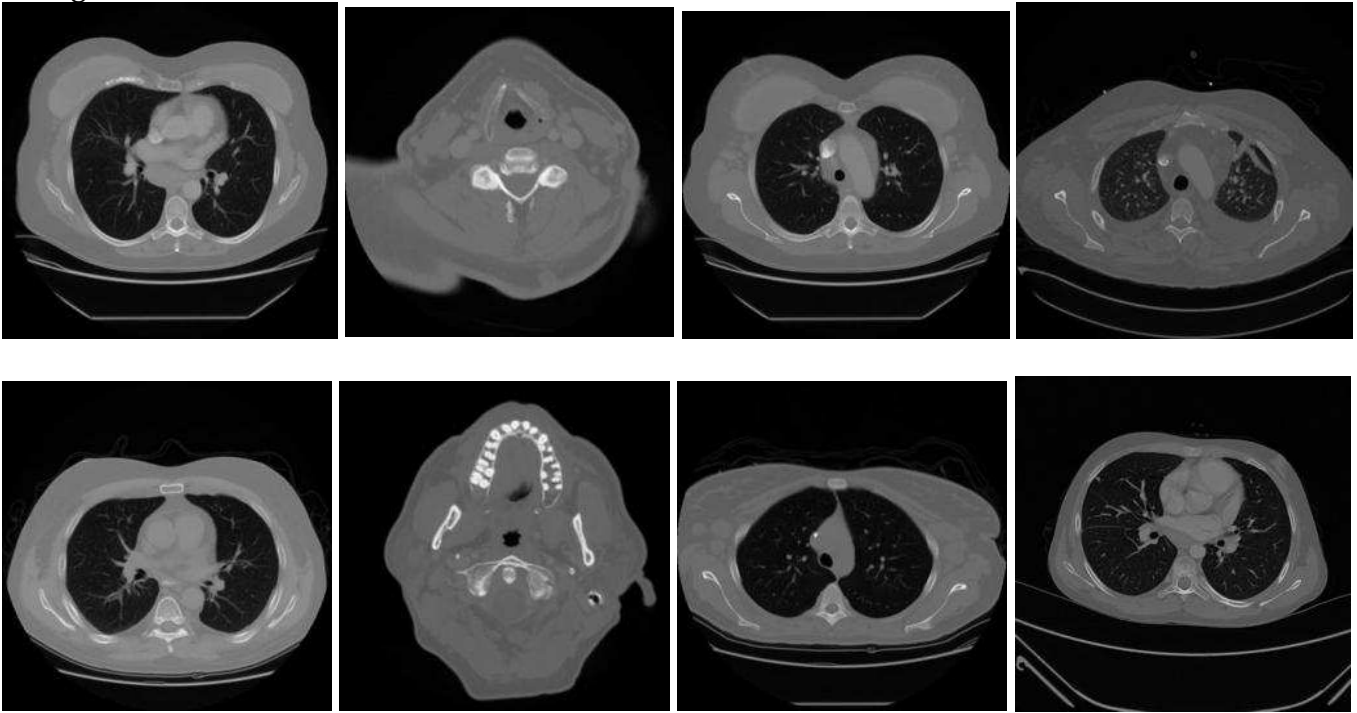
#### Topic 45:

- Lymphadenopathy.3.

- terms:

nodes,lymph,node,small,adenopathy,axillary,neck,bilateral,enlarged,inguinal,iliac,cervical,supraclavicular  
axilla,retroperitoneal,mediastinal,mesenteric,multiple,lymphoma,subcarinal,external,spleen,chest,paratr  
acheal,measuring,mediastinum,hilar,size,largest,region,periaortic,abdomen,few,large,anterior,subcentim  
eter,pelvis,several,impression,splenomegaly,thymus,hilum,also,bilaterally,upper,level,calcified,cll,history,  
1.5

- images:



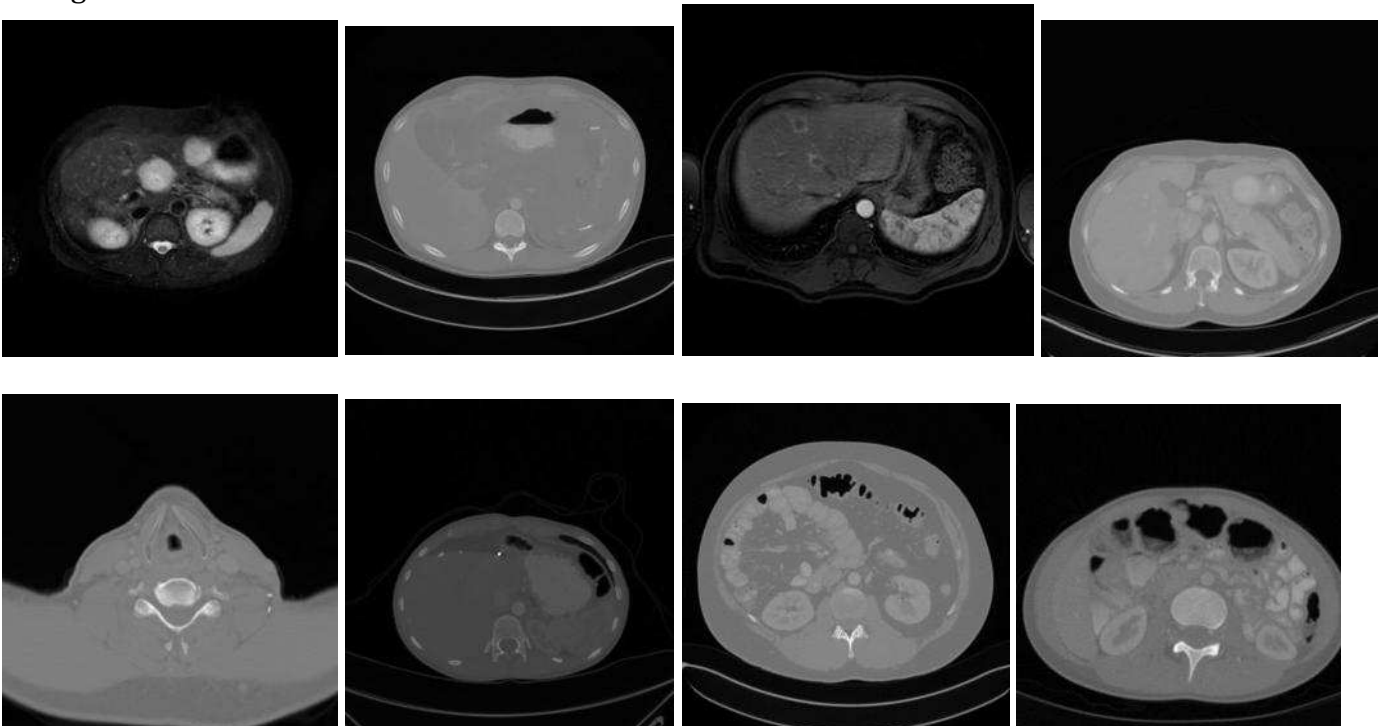
#### Topic 46:

- Cross-sectional imaging. 1. [This cluster does not contain specific terms to strongly suggest a category.]

- terms:

unremarkable, structures, skeletal, findings, abdomen, imaged, series, technique, adenopathy, pelvis, chest, scan, new, noted, within, this, visualized, performed, cardiac, compatible, comparison, effusion, pericardial, otherwise, which, pulmonary, oral, impression, intravenous, contrast, thoracic, hilar, pleural, upper, portions, non-cardiac, cts, after, pancreas, reason, axillary, mediastinal, sub, spleen, adrenals, above, separately, prior, subcentimeter, free

- images:



### Topic 47:

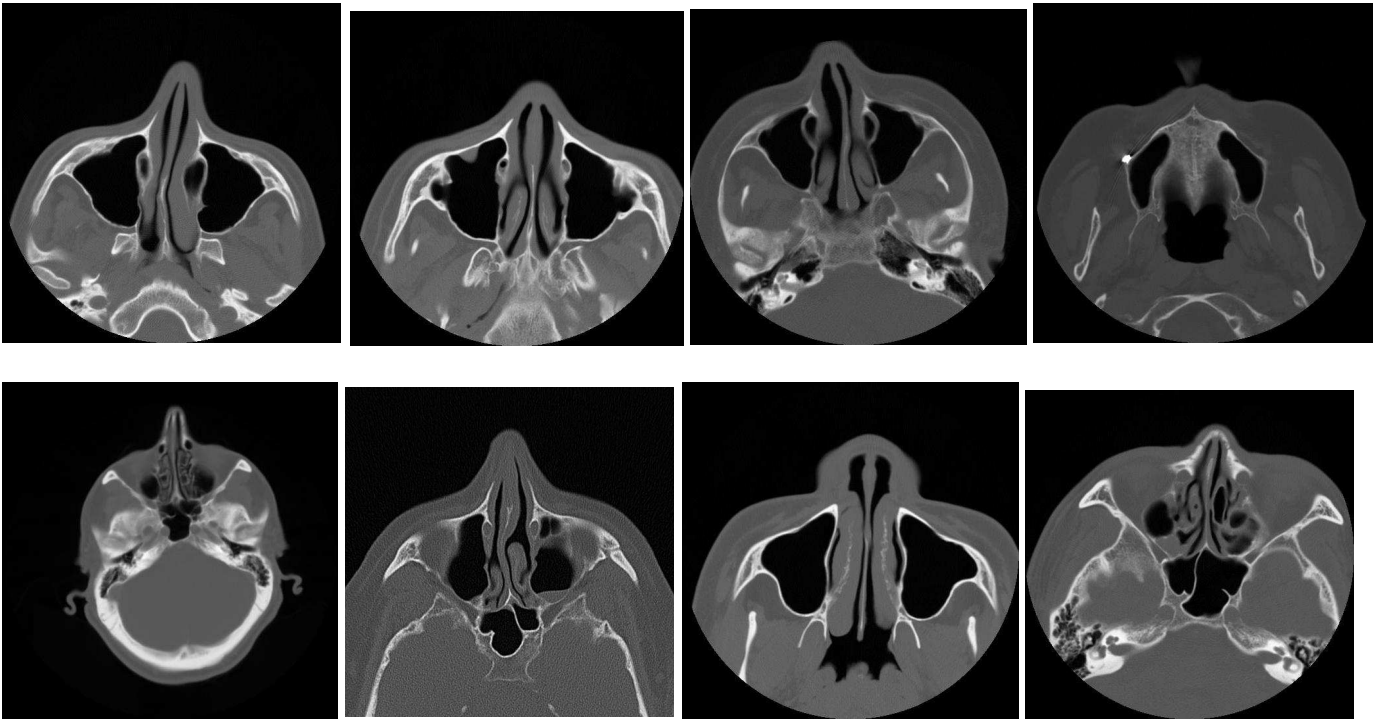
- Sinus disease. 3.

- terms:

sinus,maxillary,sinuses,mucosal,thickening,ethmoid,paranasal,air,retention,bone,cells,sphenoid,clear,frontal,findings,technique,unremarkable,impression,cyst,axial,mild,sinusitis,fluid,algorithm,orbits,mastoid,minimal,reconstructions,coronal,opacification,mucous,2.5,intracranial,tissue,mucus,bilateral,through,comparison,bilaterally,swelling,soft,air-

fluid,levels,nasal,cerebrum,portions,contrast,without,contents,visualized

- images:



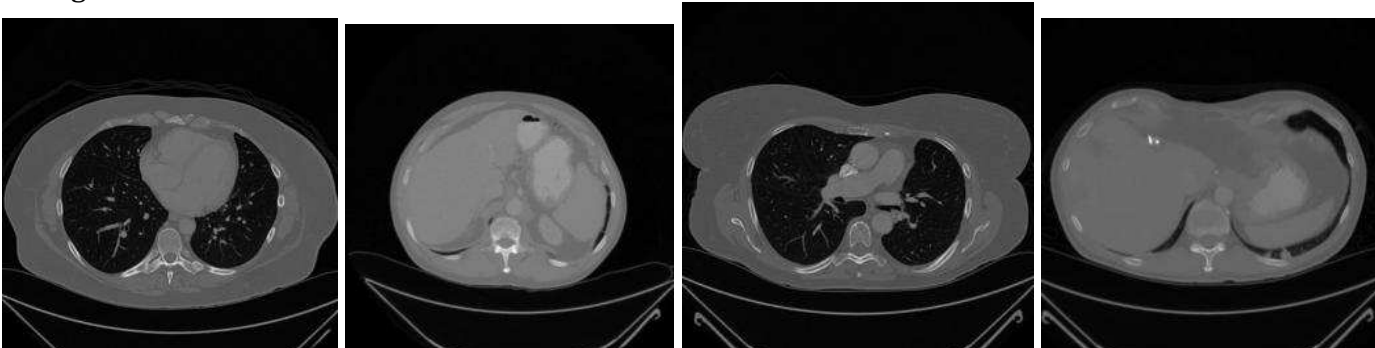
### Topic 48:

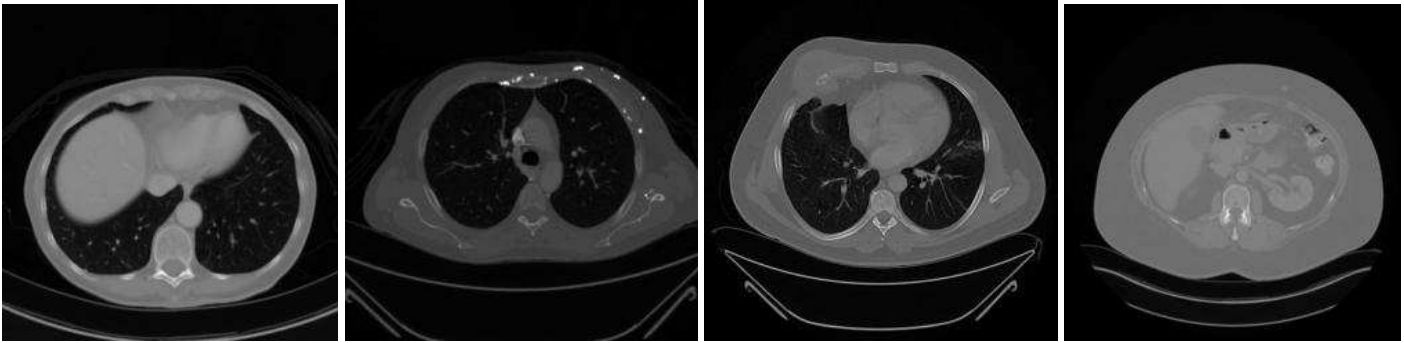
- Follow-up imaging, NOS. 1. (features, lymphadenopathy, comparison, thickening, nodularity, increased)

- terms:

unchanged,exam,prior,normal,series,abdomen,features,lymphadenopathy,last,image,similar,pelvis,minimal,chest,since,indication,which,examination,technique,contrast,comparison,postoperative,thickening,such,enhancement,bone,lymph,nodularity,small,lung>window,loops,lower,iliac,moderate,identified,pleural,regions,this,increased,assessment,upper,portion,from,liver,nodes,hypodensity,lesions,bowel,axis

- images:





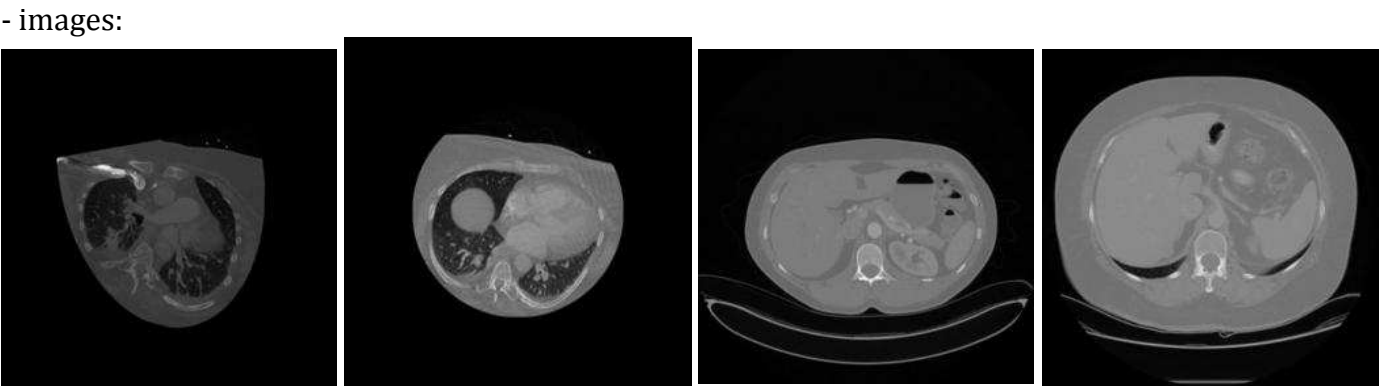
**Topic 49:**

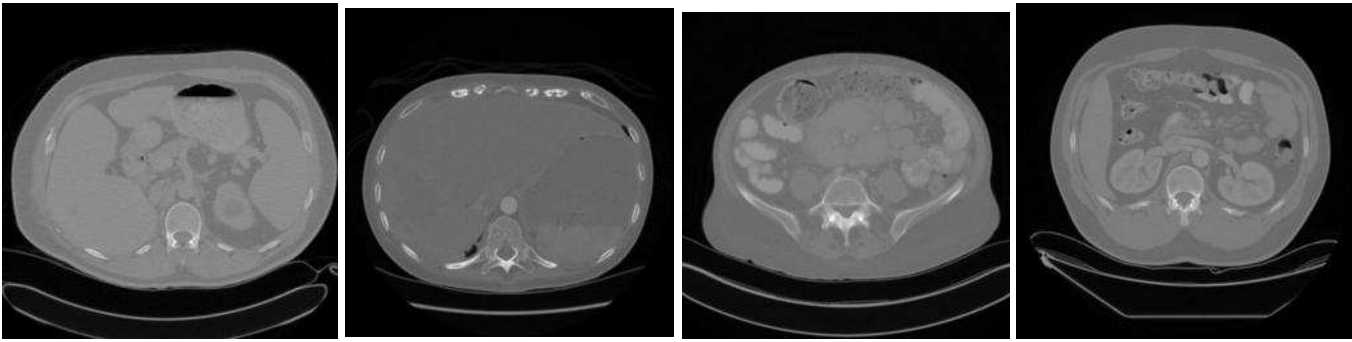
- DEXA. 3.  
 - terms:  
 t-score, gm/cm, bmd, z-score, bone, femur, minus, spine, mass, age, normal, were, values, average, 2.5, patient, score, used, adult, was, 1.0, may, densitometry, persons, lateral, peak, density, years, wards, patients, below, hip, trochanter, intertrochanter, total, impression, young, energy, absorptiometry, determine, dual, femoral, neck, instrument, following, same, obtained, made, population, comparisons

- images:  
 NO IMAGES AVAILABLE

**Topic 50:**

- Abdominal cross-sectional imaging, NOS. 2. [No specific terms to suggest a particular process or disease.]  
 - terms:  
 unremarkable, abdomen, contrast, pelvis, adenopathy, chest, oral, administered, was, spleen, liver, technique, a, adrenal, pelvic, small, pancreas, bladder, kidneys, lymphadenopathy, glands, were, mediastinal, normal, gallbladder, date, without, comparison, examination, retroperitoneal, intravenous, axial, images, unchanged, obtained, 130, findings, lesions, bowel, axillary, mass, impression, hydronephrosis, adrenals, contiguous, nodule, focal, administration, colon, mesenteric, from





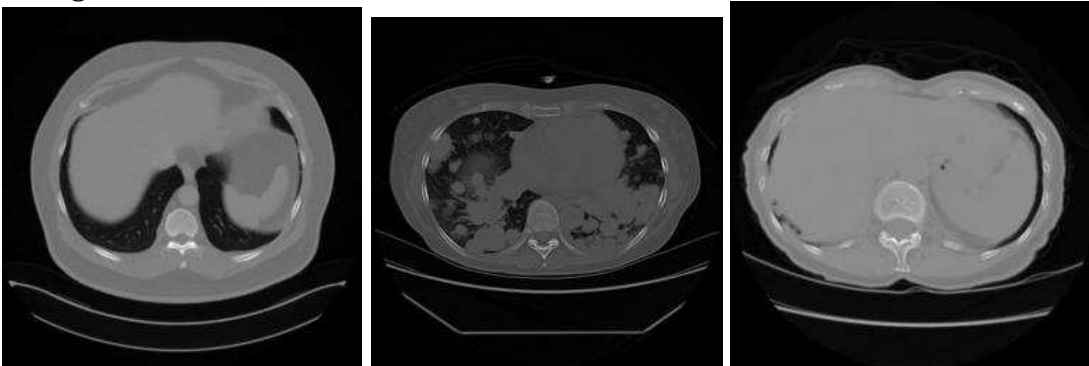
### Topic 51:

- Assessment of disease progression. 2. (more/slightly, prominent, greater, extensive, smaller, diffuse, relatively, similar, compared)

- terms:

than, more, slightly, prominent, less, some, greater, extensive, larger, but, bilaterally, also, these, appears, both, most, throughout, appear, present, smaller, diffuse, prior, well, involvement, all, disease, somewhat, side, bilateral, which, multiple, this, mild, however, particularly, areas, consistent, although, relatively, numerous, much, similar, involving, degree, overall, extent, they, suggesting, may, compared

- images:



### Topic 52:

- DEXA. 3.

- terms:

z-score, t-score, bmd, bone, density, 2.5, minus, femur, 2.0, patient, indicates, below, patients, age, gm/cm<sup>2</sup>, normal, was, 1.0, were, values, used, cause, further, warranted, its, terms, investigation, percentile, adult, average, fracture, risk, score, mass, over, general, than, less, indicate, also, abnormality, spine, above, same, range, years, comparisons, which, within, reference

- images:

NO IMAGE AVAILABLE

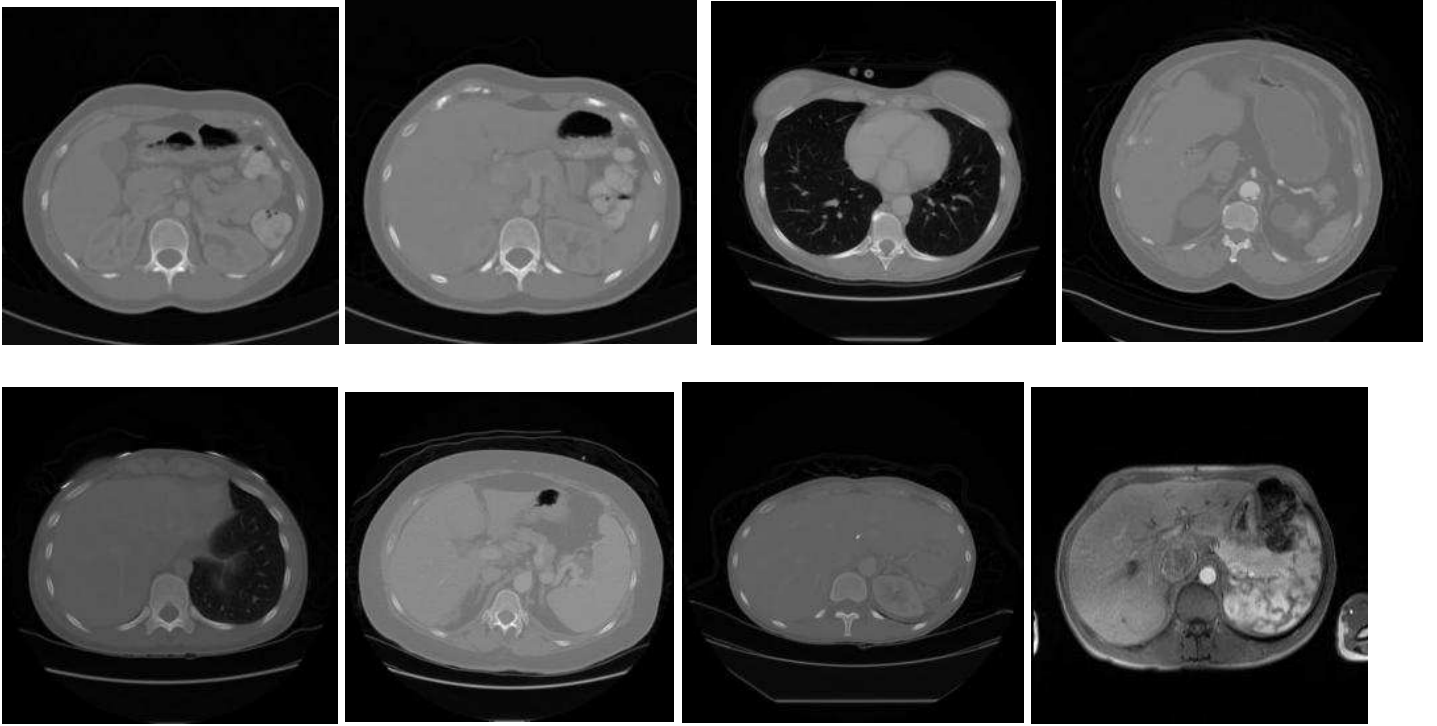
### Topic 53:

- Interpretation of examinations of outside hospital examinations. 3.

- terms:

outside, correlation, clinical, films, dated, from, suggest, submitted, recommended, significance, performed, interpretation, available, studies, review, images, read, uncertain, patient, further, pacs, evaluation, nih, hospital, center, suggested, imaging, findings, film, medical, institution, scan, indicated, marked, name, this, clinically, advised, recomb

- images:



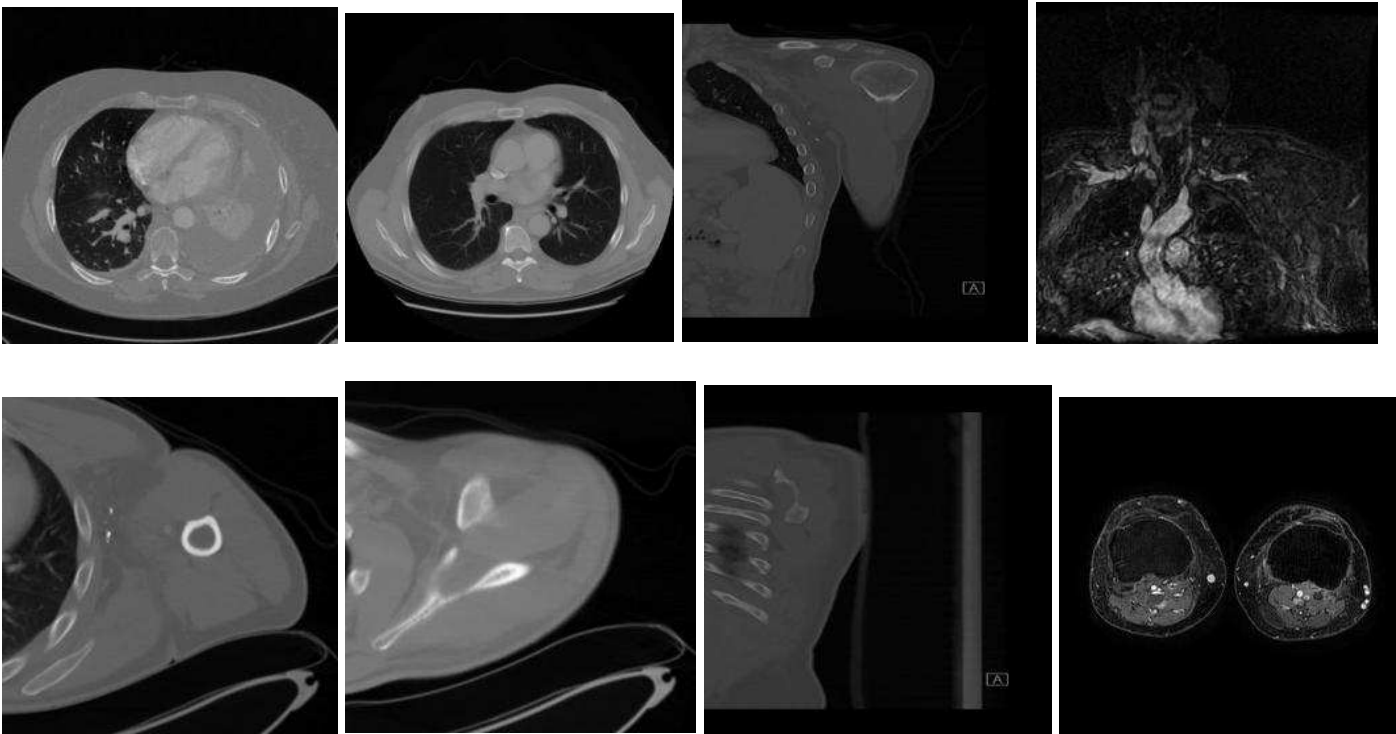
**Topic 54:**

- Venous thrombosis. 3.

- terms:

vein,veins,femoral,popliteal,normal,evidence,common,superficial,clot,lower,deep,thrombus,jugular,doppler,extremity,subclavian,ultrasound,thrombosis,upper,venous,leg,flow,internal,dvt,impression,arm,mid,thigh,axillary,extremities,brachial,basilic,bilateral,patent,visualized,calf,compression,color-flow,multiple,including,duplex,cca,swelling,using,distal,cephalic,proximal,bilaterally,ivc,venogram

- images:





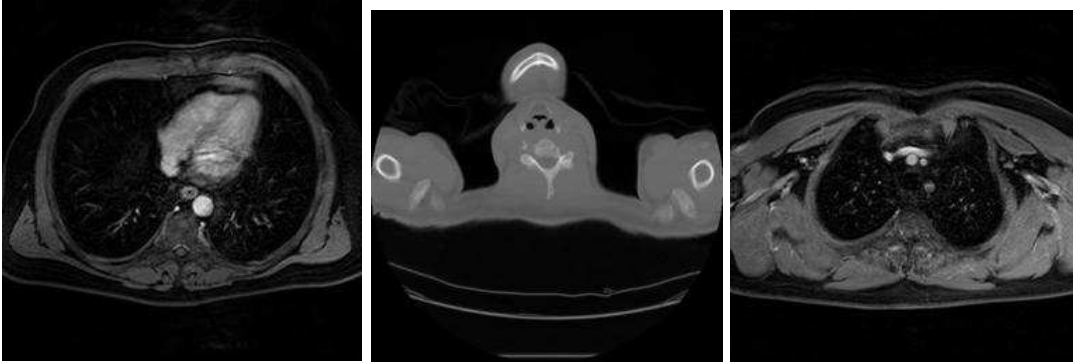
### Topic 55:

- Bone scan (MDP). 3.

- terms:

scan, bone, abnormal, was, activity, impression, following, mci, hours, increased, uptake, body, patient, whole, shows, comment, focus, disease, also, administration, approximately, performed, showed, this, posterior, metastatic, abnormalities, initial, anterior, mdp, follow, compared, previous, focal, region, degenerative, spect, injection, rib, lesions, seen, were, comments, new, which, dated, bony, skull, multiple, ribs

- images:



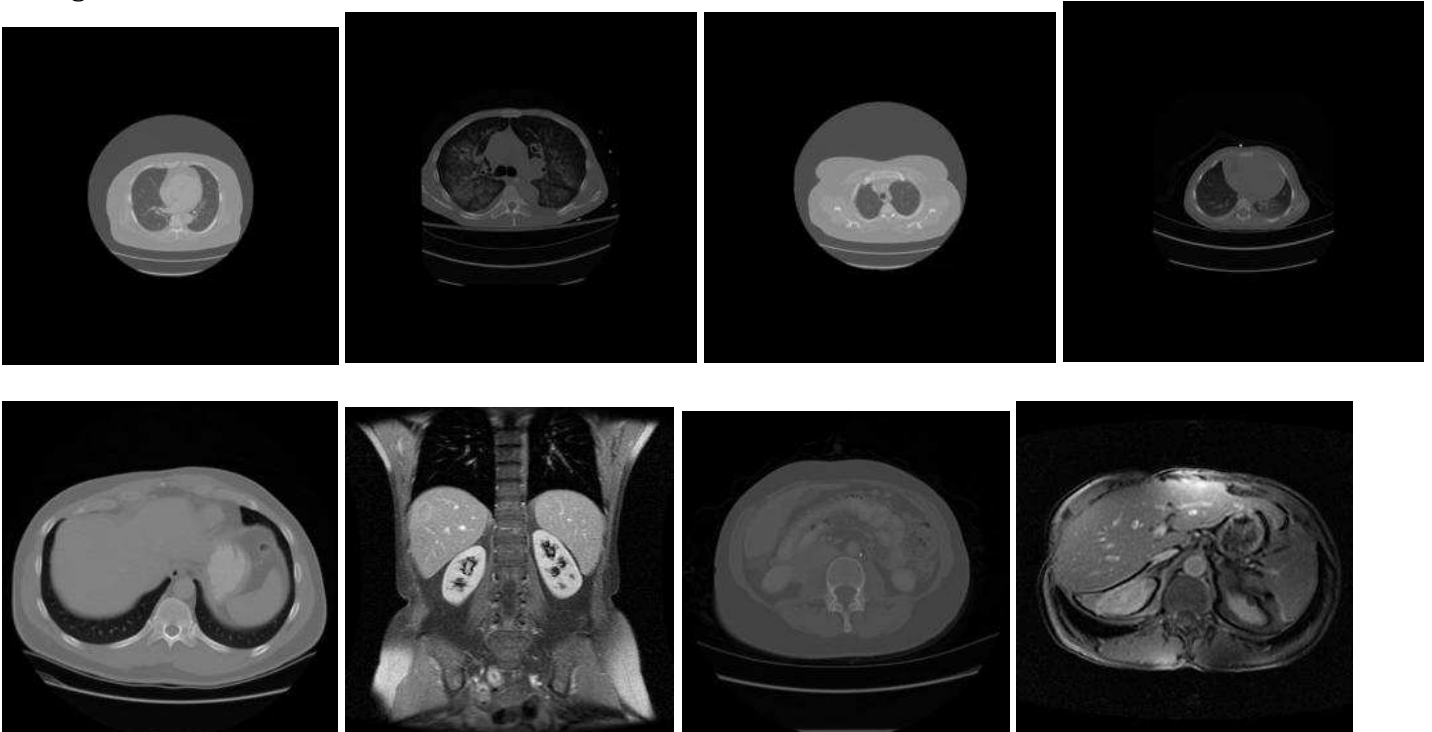
### Topic 56:

- Lesions with unspecific features and cannot be characterized. 2. [adenopathy, nonspecific, tiny, warranted, comparisons, consider, nodules, possibly, compatible, lesion]

- terms:

adenopathy, may, stable, image, evaluation, given, findings, nonspecific, not, interval, again, nodule, contrast, other, hilar, attenuation, adrenal, clinically, tiny, warranted, significantly, relate, pelvic, changed, abdominal, comparisons, intravenous, noted, liver, mediastinal, procedure, consider, nodules, axillary, low, further, slightly, small, noncontrast, possibly, oral, lesion, gallbladder, wall, possible, but, compatible, pulmonary, pleural, lung

- images:



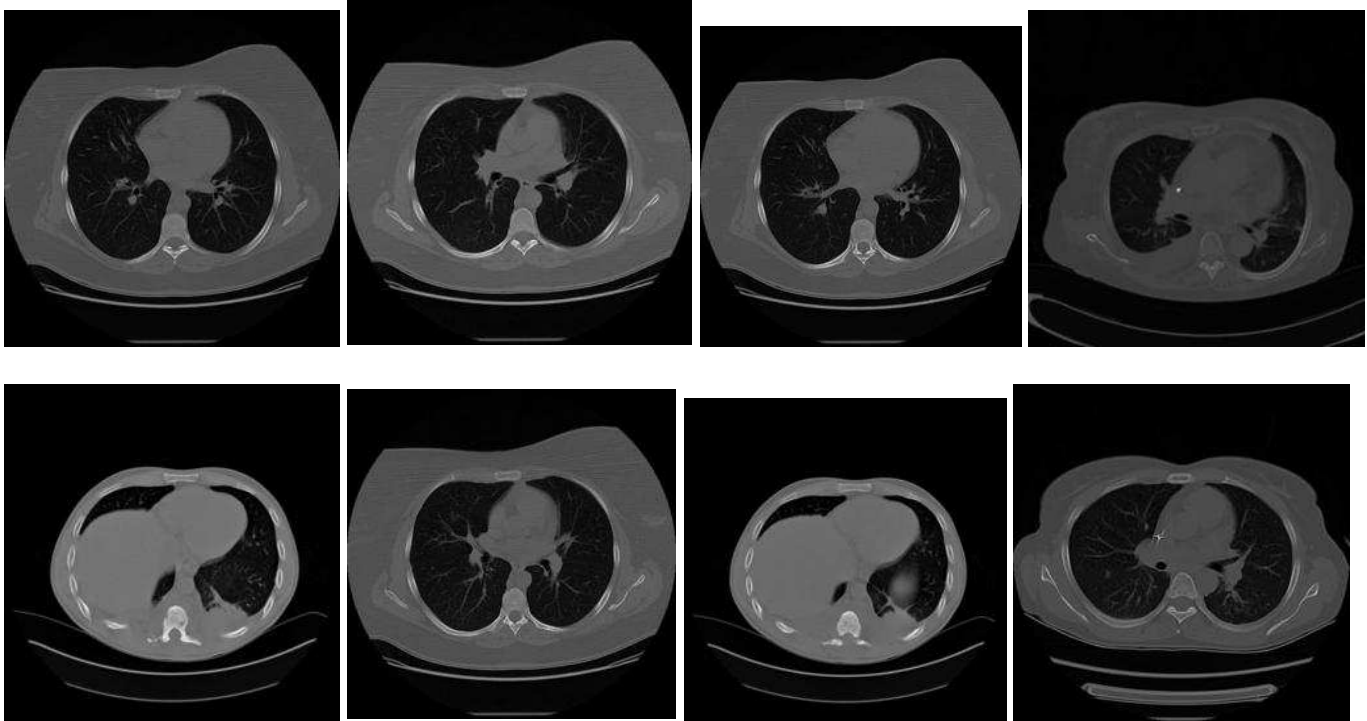
### Topic 57:

- Non-standard chest imaging. [Terms which indicate view is obstructed (positional, projected, possible, leads, ekg, foreign, indicated, pic, artifact, rotation)]

- terms:

marked, minimal, chest, since, number, except, two, accession, other, compatible, images, appearing, one, and/or, positional, difference, projected, over, lung, catheter, view, change, unchanged, image, pa/lateral, inspiratory, lower, surgery, history, abnormality, possibly, venous, leads, ratio, ekg, cardiothoracic, exclude, lungs, possible, foreign, can, indicated, clinically, pic, frontal, due, advise, artifact, matter, rotation

- images:



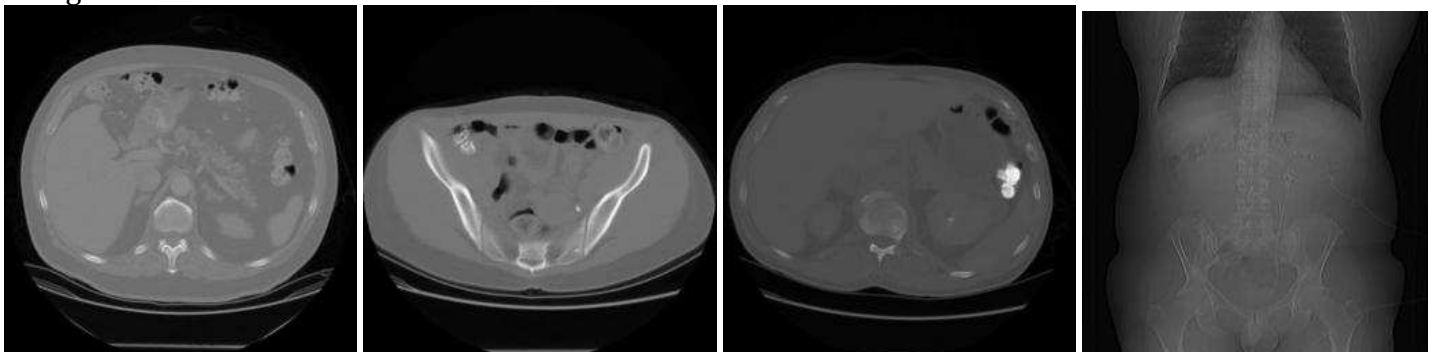
### Topic 58:

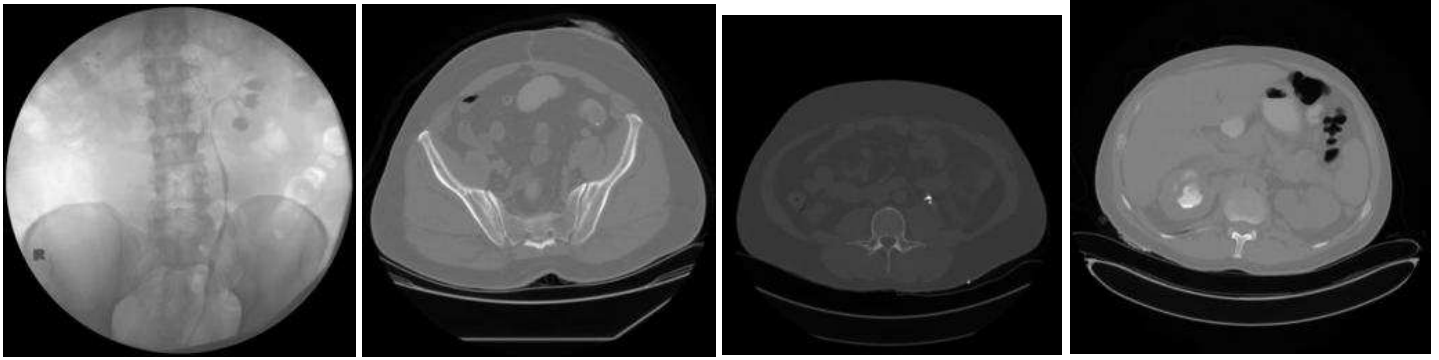
- Renal scintigraphy. 3.

- terms:

was, bladder, patient, renal, kidney, images, after, mci, urinary, both, ureter, collecting, stent, shows, lung, minute, system, function, impression, perfusion, flow, filling, renogram, defects, delayed, obstruction, approximately, ventilation, activity, normal, kidneys, differential, defect, performed, following, evidence, show, this, showed, ureteral, comment, scan, that, injection, from, excretion, were, nephrostomy, imaged, initial

- images:





### Topic 59:

- Research PET. 3.

- terms:

mci,f-18,c-11,acid,fluorodopamine,received,research,affect,results,making,patient,comments,date,purposes,was,intended,performed,this,not,fdg,fluorodopa,solely,carbon,o-15,monoxide,ammonia,arachidonic,fcway,raclopride,clinical-decision,cyclofoxy,water,flumazenil,pet,dasb,dha,\_study,4.5,160,pbr28,110,180,fallypride,nnc-112,140,rolipram,leucine,spa,2.5,1.04

- images:

NO IMAGES AVAILABLE

### Topic 60:

- Bone age study. 3.

- terms:

age,bone,years,months,hand,according,standard,pyle,greulich,about,wrist,chronological,findings,skeletal,maturation,normal,comparison,growth,interval,since,history,view,deviation,noted,chronologic,impression,estimated,examination,year,old,standards,short,most,approximately,month,films,foundation,mean,brus,h,stature,syndrome,correlates,delayed,male,undiagnosed,plates,closely,previous,distal,boy

- images:

NO IMAGE AVAILABLE

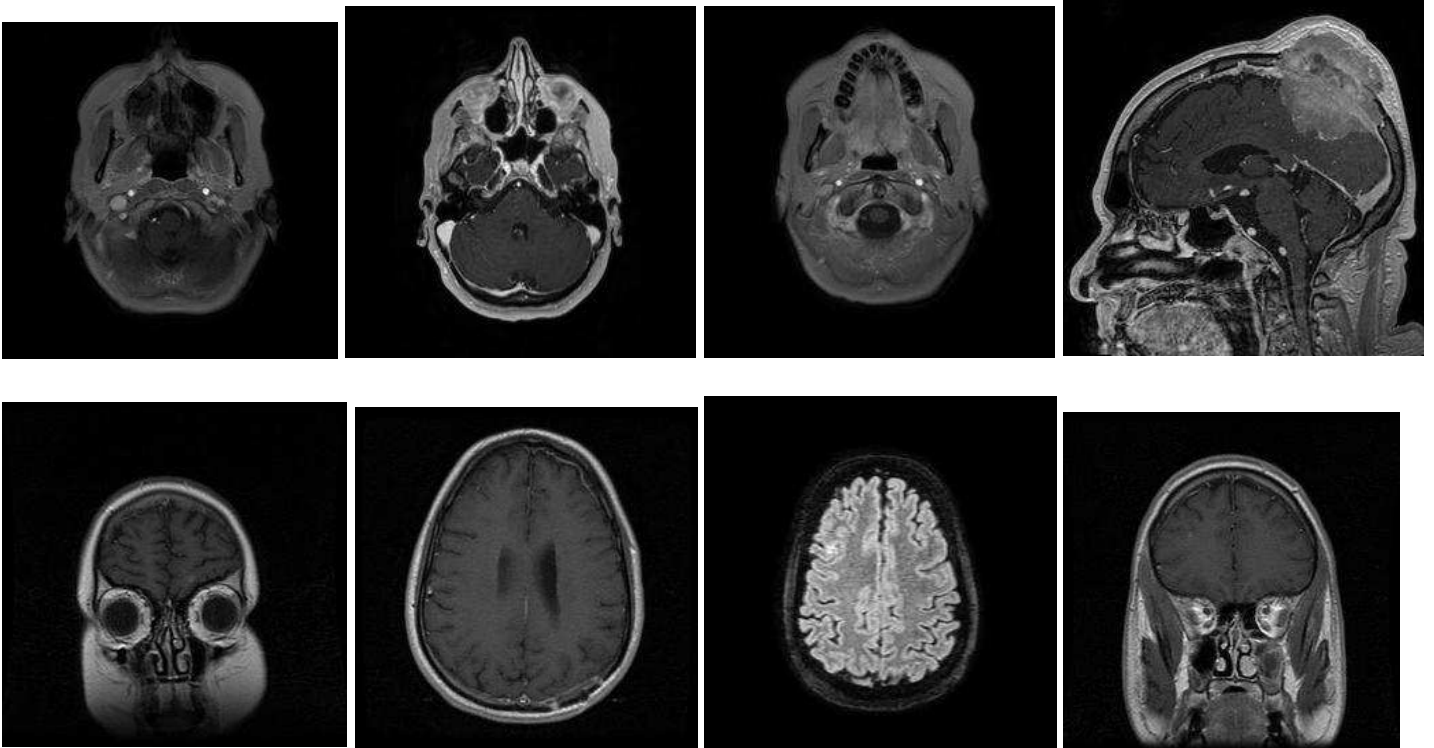
### Topic 61:

- Brain tumor protocol MRI. 3.

- terms:

images,were,t1-weighted,axial,acquired,contrast,resection,lobe,enhancement,cavity,administration, mass,brain,margin,frontal,perfusion,sagittal,lesion,comparison,demonstrate,during,mri,perfusion-weighted,negative,enhancing,unchanged,integral,was,flair,unremarkable,performed,prior,generated,not,registration,involving,deposition,parietal,maps,time,elevated,clear,hemosiderin,previous,temporal,from,intravenous,agent,within,enhanced

- images:



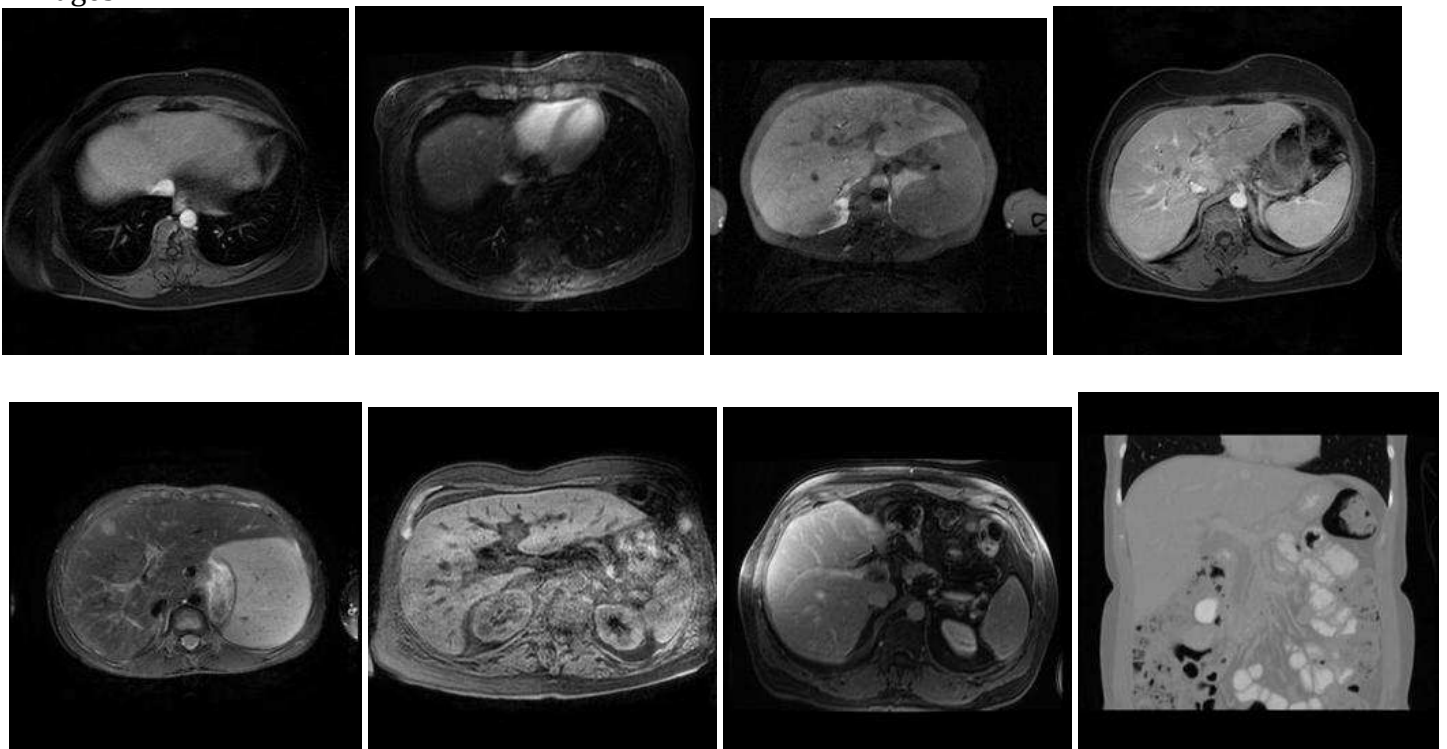
## Topic 62:

- Ultrasound liver. 3. [Liver ultrasound terms (duct, flow, texture, ultrasound).]

- terms:

liver,normal,gallbladder,spleen,portal,pancreas,duct,biliary,bile,focal,vein,flow,hepatic,common,intrahepatic,impression,lesions,abdomen,dilatation,patent,fatty,ascites,ducts,shows,not,dilated,kidneys,enlarged,size,towards,texture,directed,normally,infiltration,gallstones,wall,ultrasound,measuring,abdominal,appear,however,both,upper,somewhat,around,pancreatic,limited,ductal,does,views

- images:



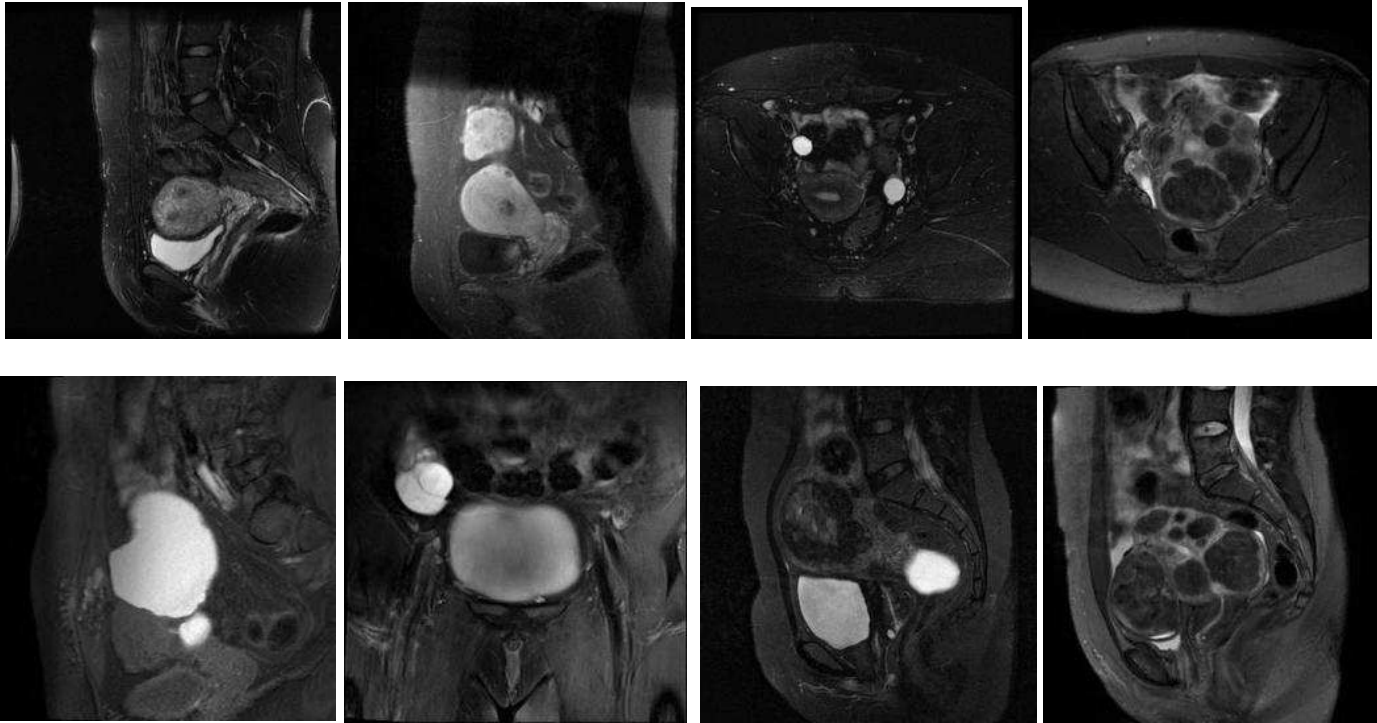
### Topic 63:

- Pelvic (female reproductive tract) ultrasound. 2. [Some words suggest ultrasound (transvaginal, hypoechoic). However, all images are from cross-sectional examinations by virtue of how this project was designed.]

- terms:

measures,uterus,measuring,ovary,pelvis,ultrasound,diameter,about,small,transverse,cyst,seen,ovaries,ovarian,volume,follicles,uterine,normal,fibroid,mass,impression,fibroids,multiple,size,both,1.5,approximately,pelvic,1.7,1.2,1.4,adnexal,thickness,1.3,1.6,1.8,measured,dimensions,dimension,transvaginal,endometrial,2.5,testis,endometrium,2.2,fluid,2.3,hypoechoic,large,1.9

- images:



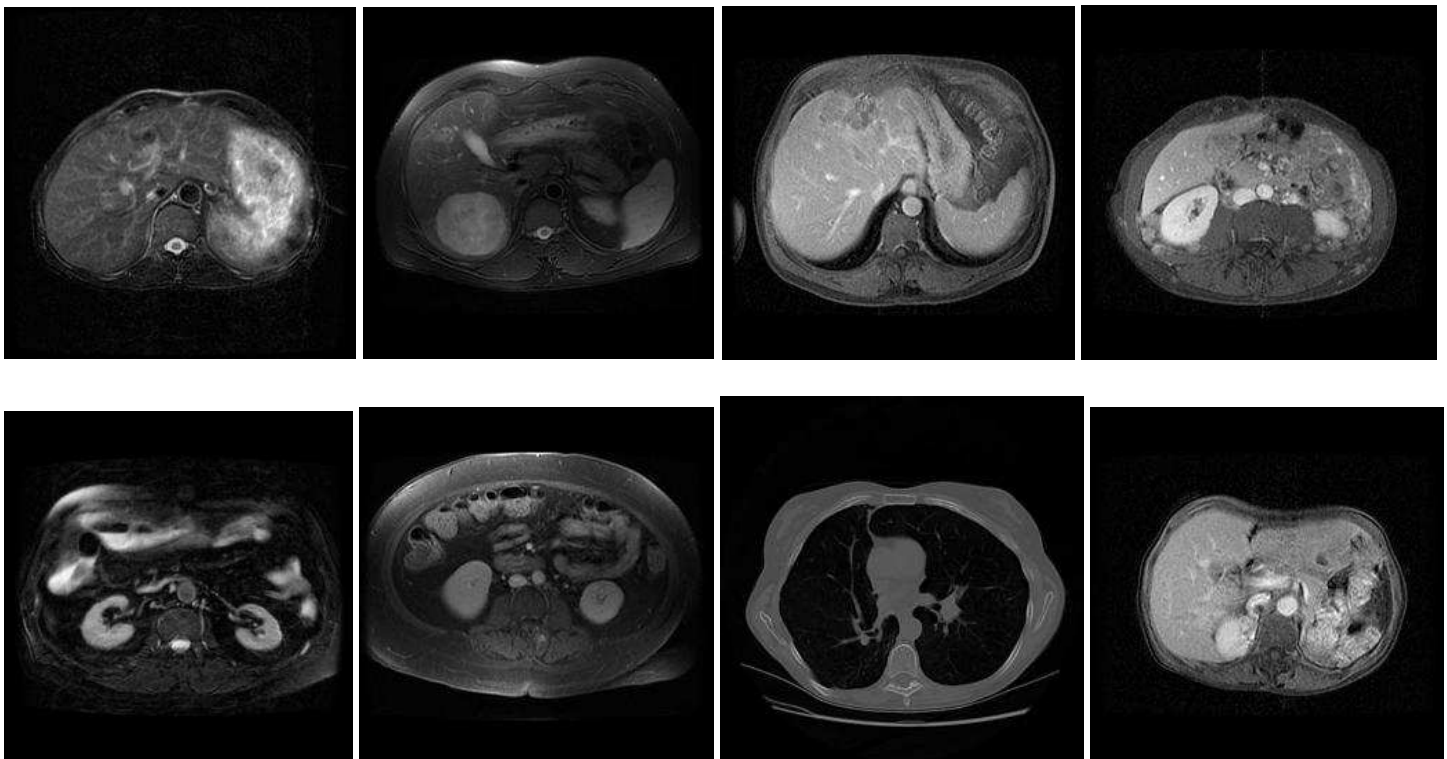
### Topic 64:

- Dates. 2. [Unclear how this became a word cluster.]

- terms:

2001,compared,2004,previous,2002,october,change,2003,november,chest,history,2006,september,january,july,2000,2005,august,december,june,march,april,february,may,since,obtained,unchanged,from,were,little,prior,recent,impression,lateral,x-ray,some,shows,not,mediastinum,studies,enlarged,appears,1999,significant,status-post,appear,most,show,2007,evident

- images:



### Topic 65:

- Fluoroscopically guided intervention, lumbar puncture or central venous catheter placement. 3.

- terms:

was,patient,procedure,catheter,placed,fluoroscopic,under,guidance,were,placement,puncture,into,vein,sterile,using,jugular,internal,ultrasound,sedation,site,consent,tolerated,french,needle,complications,informed,well,lumen,performed,lumbar,impression,prepped,successful,access,given,local,skin,fluoroscopy,draped,conscious,pressure,obtained,csf,technique,table,lidocaine,used,following,immediate,anesthesia

- images:

NO IMAGES AVAILABLE

### Topic 66:

- Chest radiograph template. 3.

- terms:

chest,lateral,lungs,clear,comparison,heart,impression,normal,views,silhouette,evidence,pulmonary,acute,cardiac,infiltrate,infiltrates,effusions,x-ray,findings,pleural,mediastinal,cardiomediastinal,effusion,frontal,films,history,dated,size,view,contours,lung,prior,interstitial,pneumothorax,disease,unremarkable,markings,nodules,examination,radiograph,vascularity,mediastinum,clips,costophrenic,seen,radiographs,angles,aorta,demonstrate,available

- images:

NO IMAGES AVAILABLE

### Topic 67:

- Neurofibromatosis protocol imaging. 3.

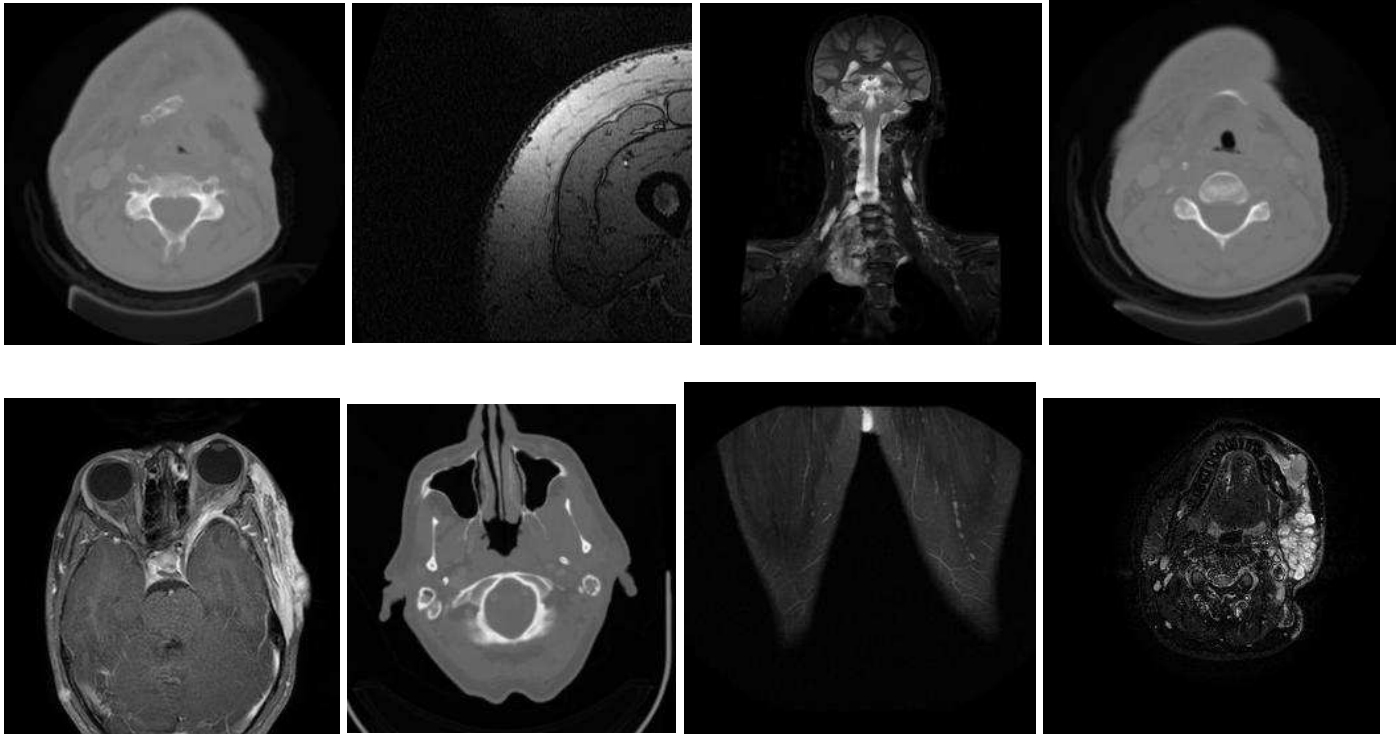
- terms:

mass,tissue,soft,large,subcutaneous,anterior,into,posterior,extending,along,wall,masses,thigh,muscle,tissues,also,region,from,extends,level,lower,involving,tumor,extensive,plexiform,adjacent,side,medial,extensi



on,skin,neurofibromas,upper,neurofibroma,muscles,aspect,edema,superior,fat,involvement,inferior,multi  
ple,paraspinal,just,this,space,area,neurofibromatosis,well,nf1,above

- images:



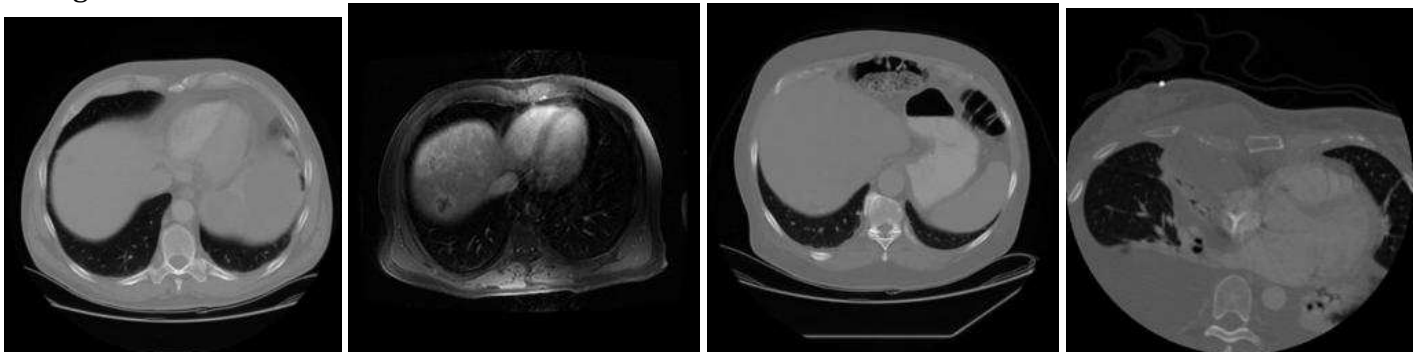
### Topic 68:

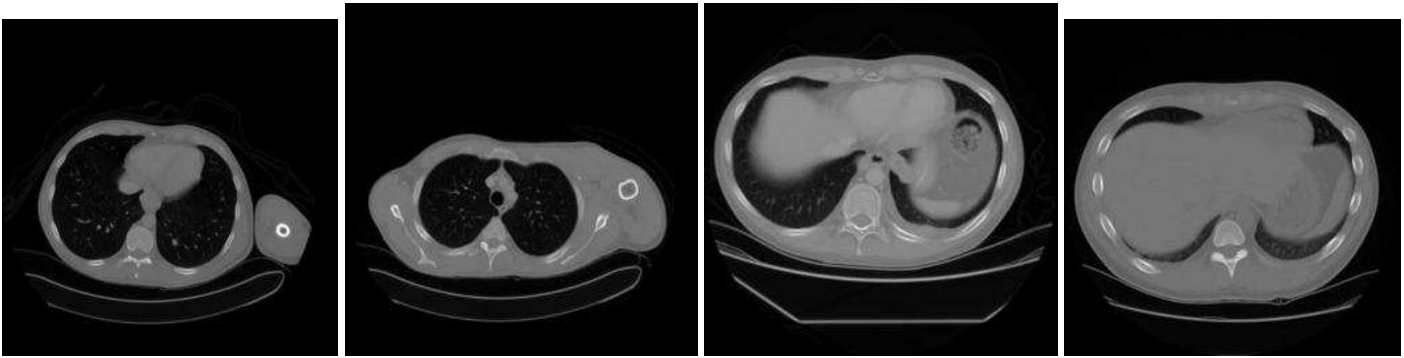
- Interval change. 3. (previous\*, increased, size, decreased, slight, present, change, significant, removed, improvement, development, current, resol\*, larger, longer, remain, residual)

- terms:

has,been,previous,interval,size,increased,compared,previously,have,decreased,now,since,again,increase,slightly,new,was,decrease,change,which,that,from,present,slight,resolved,significant,prior,removed,improvement,dated,however,today,made,development,current,seen,also,still,improved,this,resolution,remains,some,large,longer,remain,but,residual,appears,overall

- images:





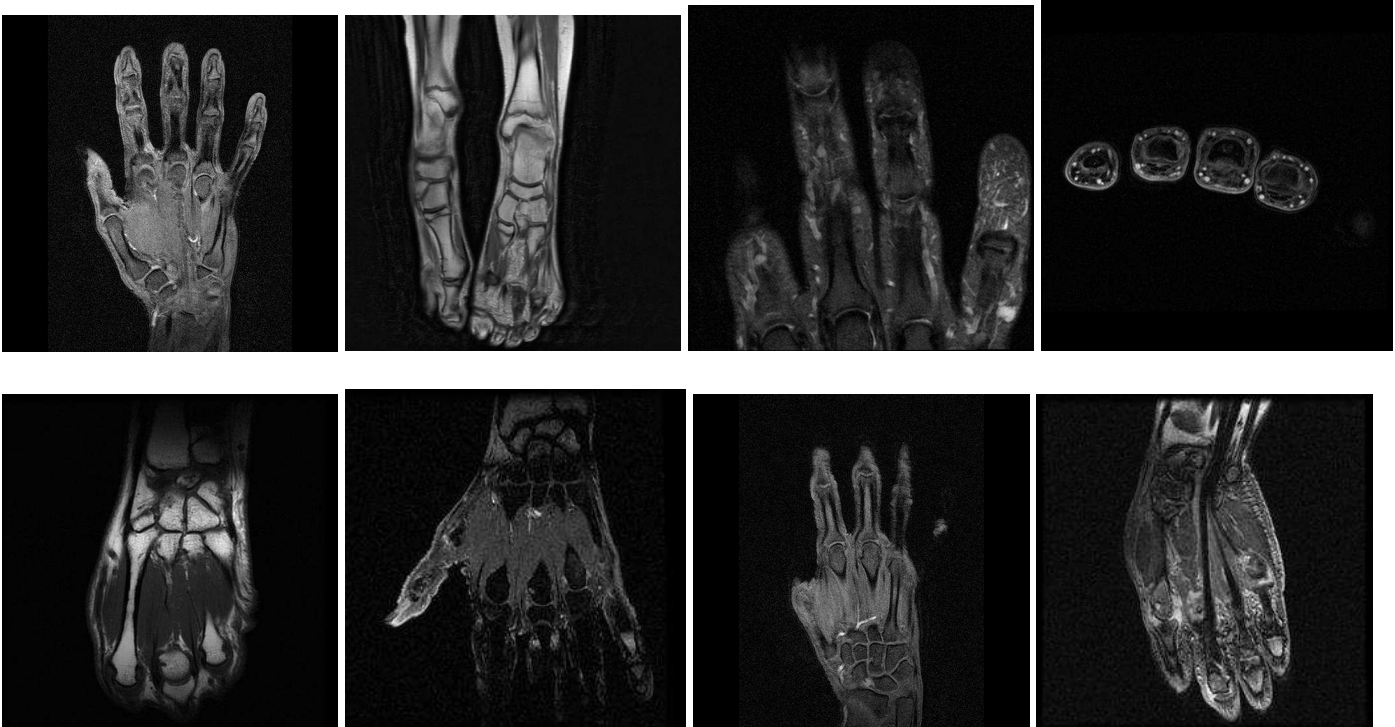
### Topic 69:

- Arthritis imaging. 3.

- terms:

joint, views, hands, lateral, evidence, joints, feet, both, wrists, bilateral, oblique, knees, findings, erosions, erosion, bony, soft, arthrosis, ankle, tissue, foot, distal, narrowing, ankles, bilaterally, space, wrist, fracture, hand, impression, changes, first, arthritis, erosive, history, calcification, small, knee, osteopenia, second, minimal, fifth, mild, third, proximal, view, metatarsal, medial, metacarpal, swelling

- images:



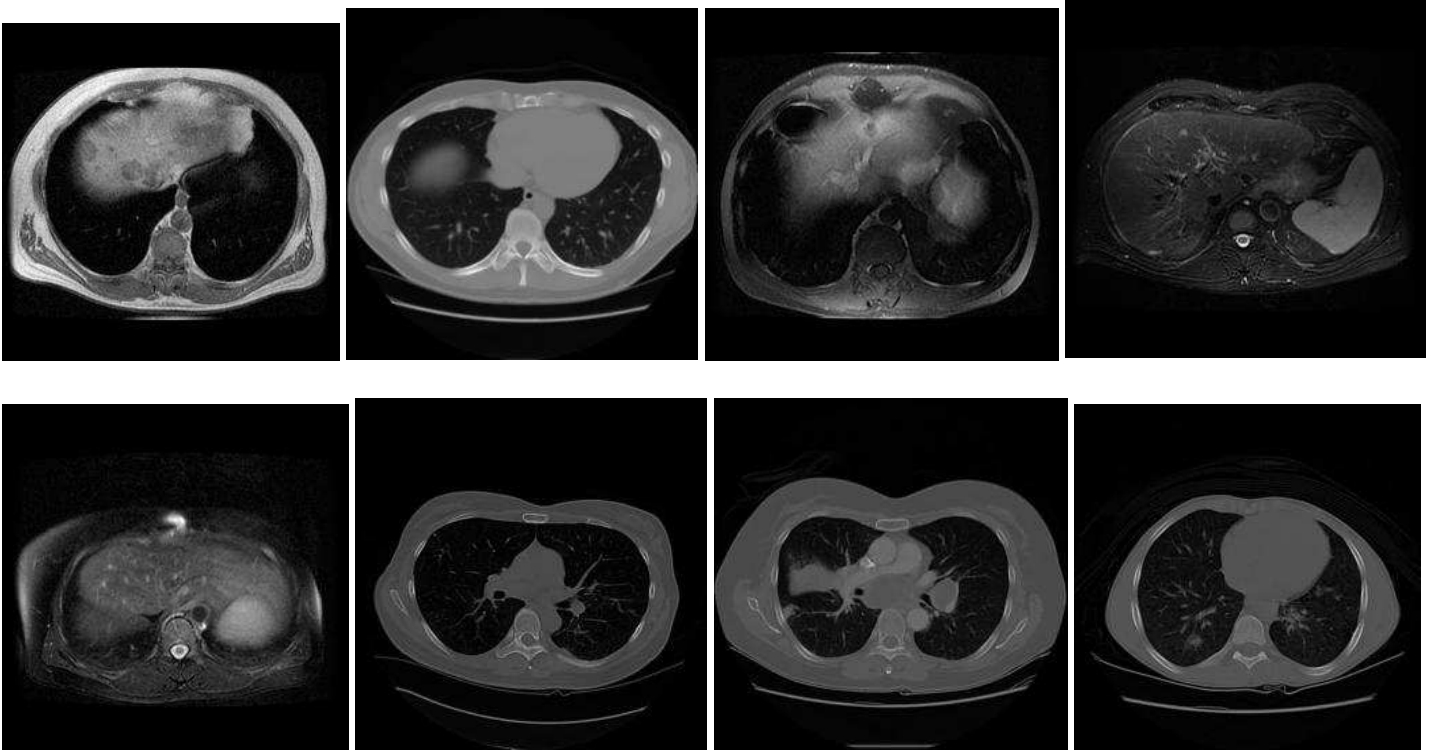
### Topic 70:

- Chest imaging, follow-up. (again, change\*, significantly, compare\*, since, new, previous, detected).

- terms:

seen, last, obtained, not, again, also, changed, well, chest, significantly, lung, through, compared, region, sections, noted, appearance, scan, defined, since, nodular, present, changes, density, comparison, made, have, side, this, new, areas, small, two, significant, densities, which, ill, axial, field, fields, films, both, detected, previous, area, findings, some, these, they, mid

- images:



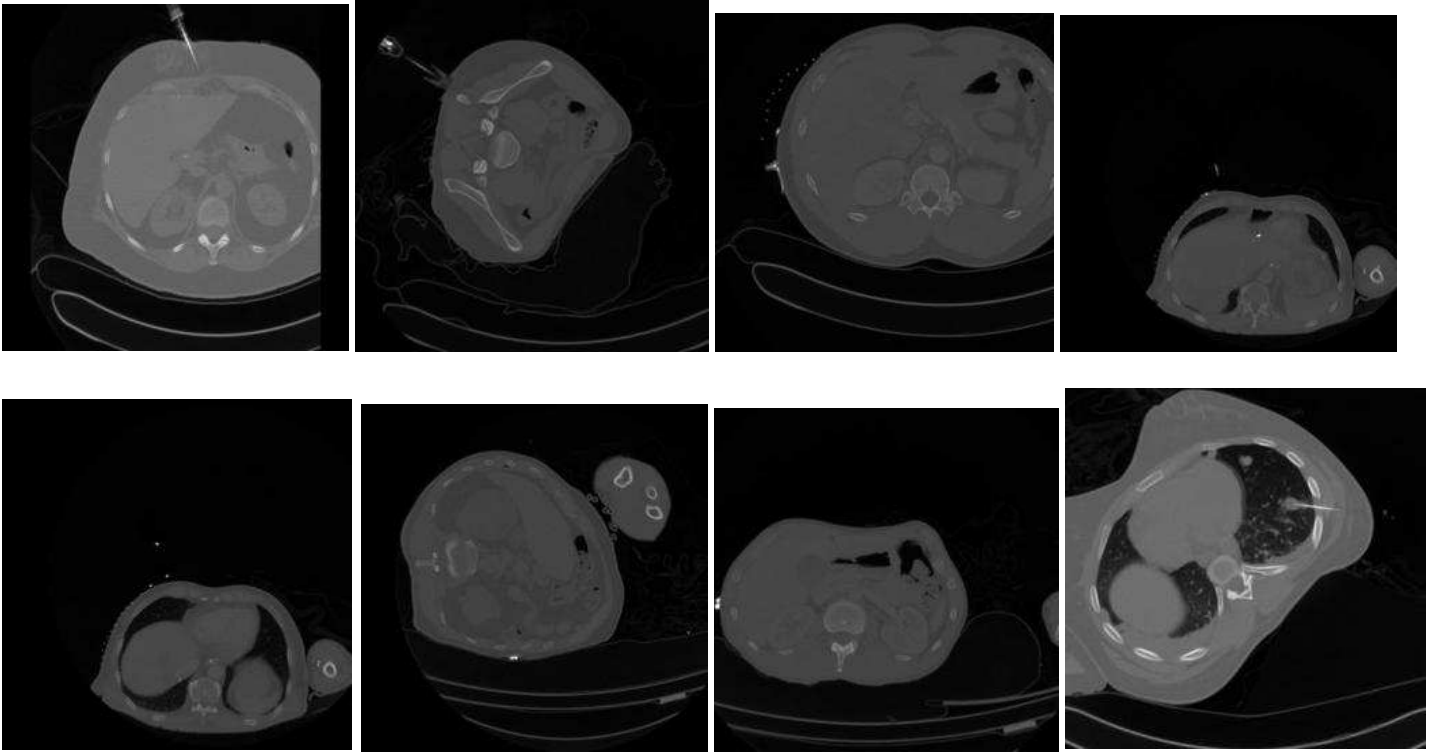
**Topic 71:**

- Image-guided liver biopsy. 3.

- terms:

was, biopsy, ultrasound, were, patient, procedure, needle, performed, guided, guidance, then, using, core, following, obtained, well, informed, biopsies, consent, under, complications, gauge, anesthesia, after, from, technique, immediate, given, lidocaine, this, into, used, mass, tolerated, specimens, local, achieved, procedural, placed, sedation, findings, targeted, fine, without, sterile, liver, aspiration, fusion, conscious, provided

- images:



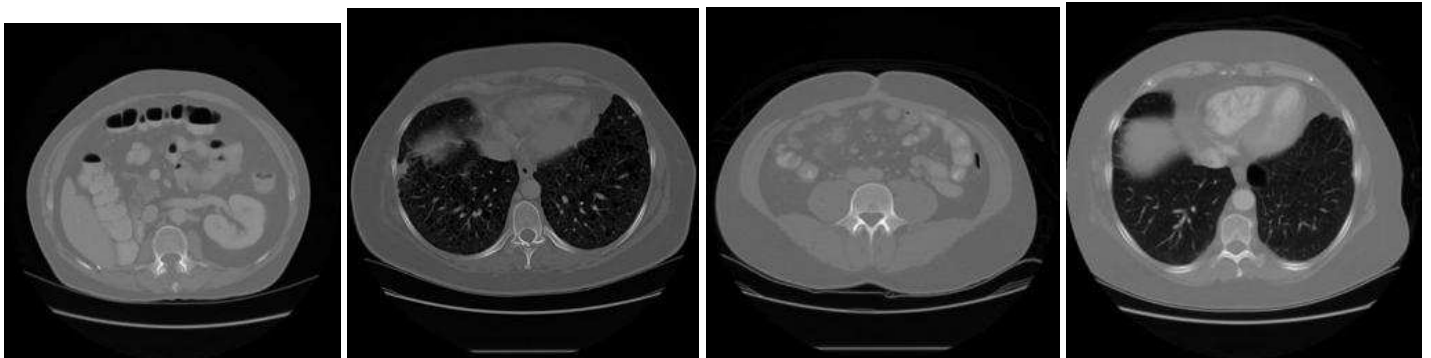
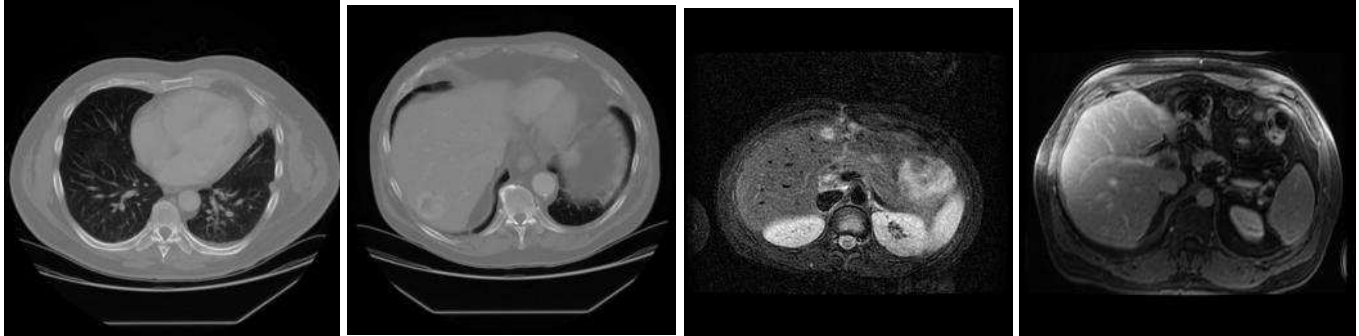
## Topic 72:

- Indeterminant lesion. 2. (seen, minimal, previous, unchanged, tiny, again, probably, since, changes, comparing, incidentally, similar, subtle, suggestion, new, calcification).

- terms:

noted, seen, examination, minimal, also, evidence, small, previous, scan, few, findings, unchanged, both, use, area, tiny, other, near, intravenous, again, performed, very, bilateral, some, probably, since, changes, comparing, incidentally, contrast, region, similar, impression, nodule, subtle, which, appears, moderate, anterior, posterior, slightly, suggestion, around, several, new, superior, relatively, calcification, history, from

- images:



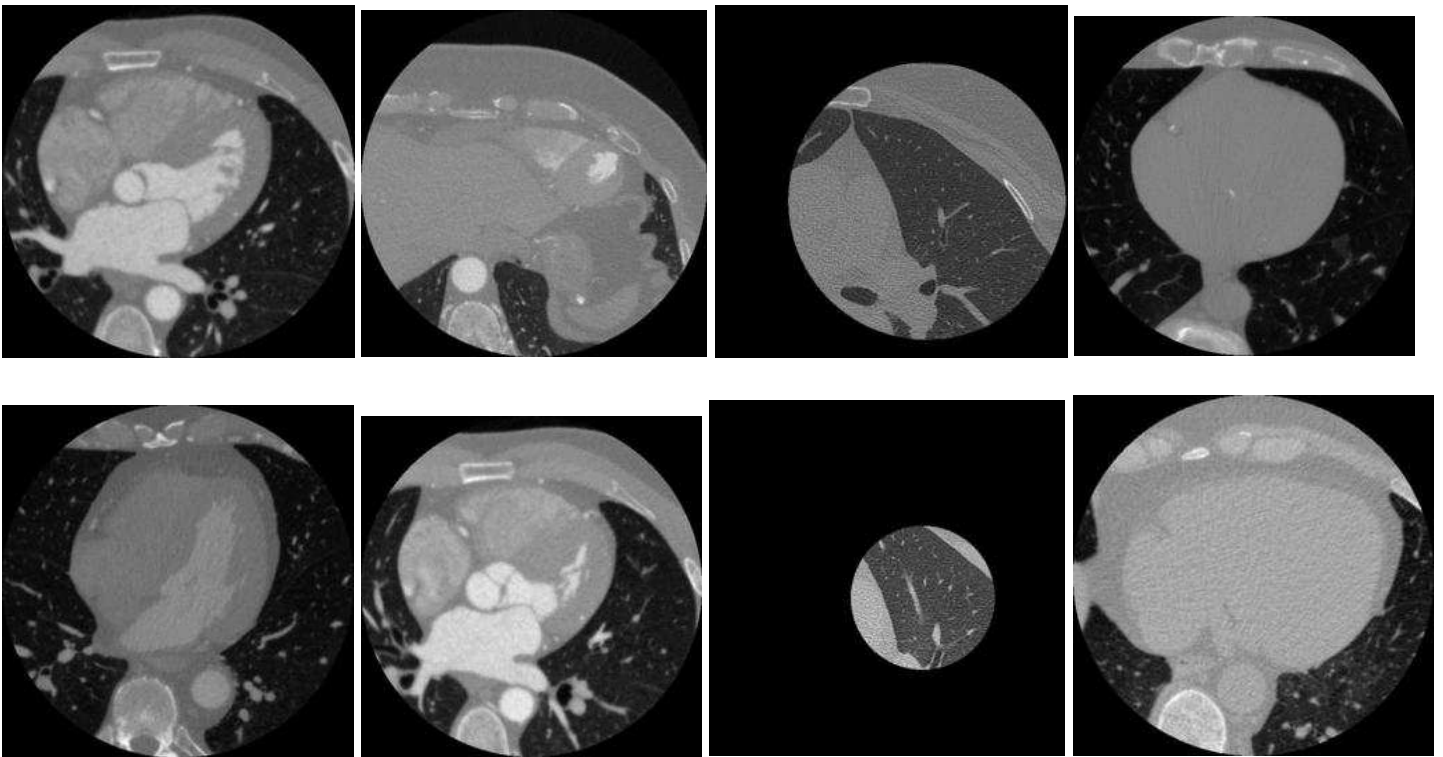
## Topic 73:

- Reporting critical findings. 3.

- terms:

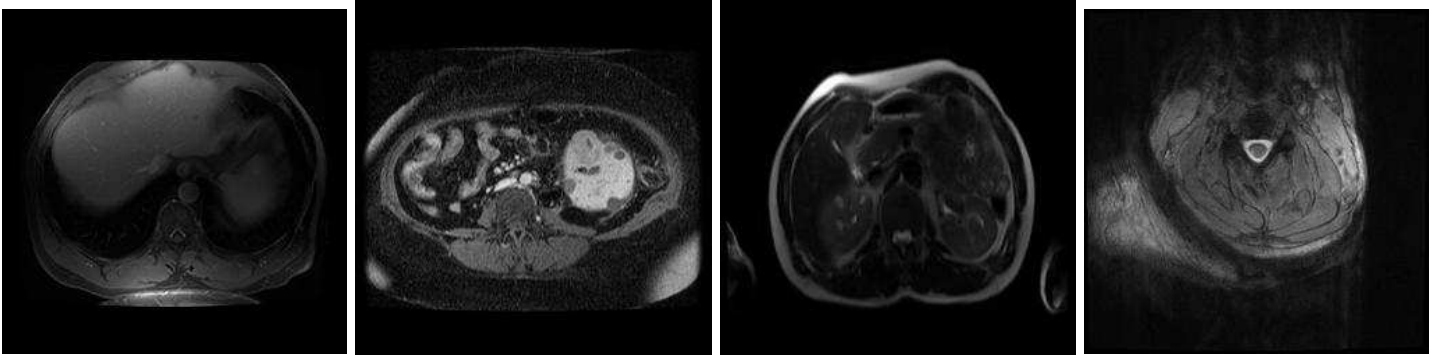
addendum, discussed, test, dictation, this, p.m, please, reviewed, see, signed, results, date, original, above, due, who, below, dictated, note, only, findings, section, signature, telephone, addended, was, here, a.m, patient, reported, 30, result, line, understanding, from, should, critical, end, friday, time, wednesday, order, thursday, under, facilitate, correct, details, evidently, monday, technical

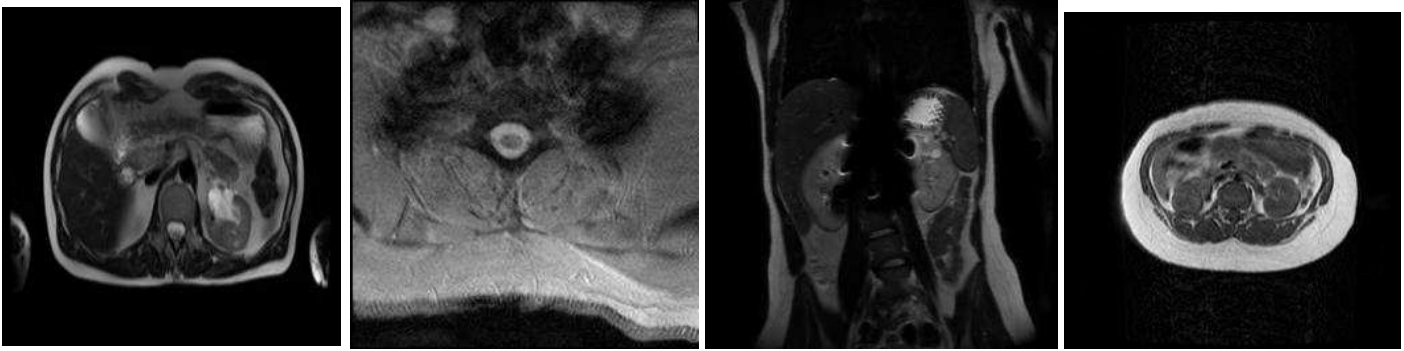
- images:



**Topic 74:**

- Instrumentation artifact limiting interpretation. 2. (limited, motion, artifact\*, metallic, obvious, gross, suboptimal)
- terms:  
 images,obtained,were,limited,findings,from,axial,technique,without,contrast,due,motion,artifact,evaluation,prior,comparison,examination,this,mri,portions,impression,through,not,artifacts,indication,identified,patient,demonstrate,intravenous,abnormalities,available,metallic,abnormality,lack,visualized,significant,evidence,exam,obvious,gross,only,evaluate,syndrome,suboptimal,history,metal,included,arising,evaluate d,assessment
- images:





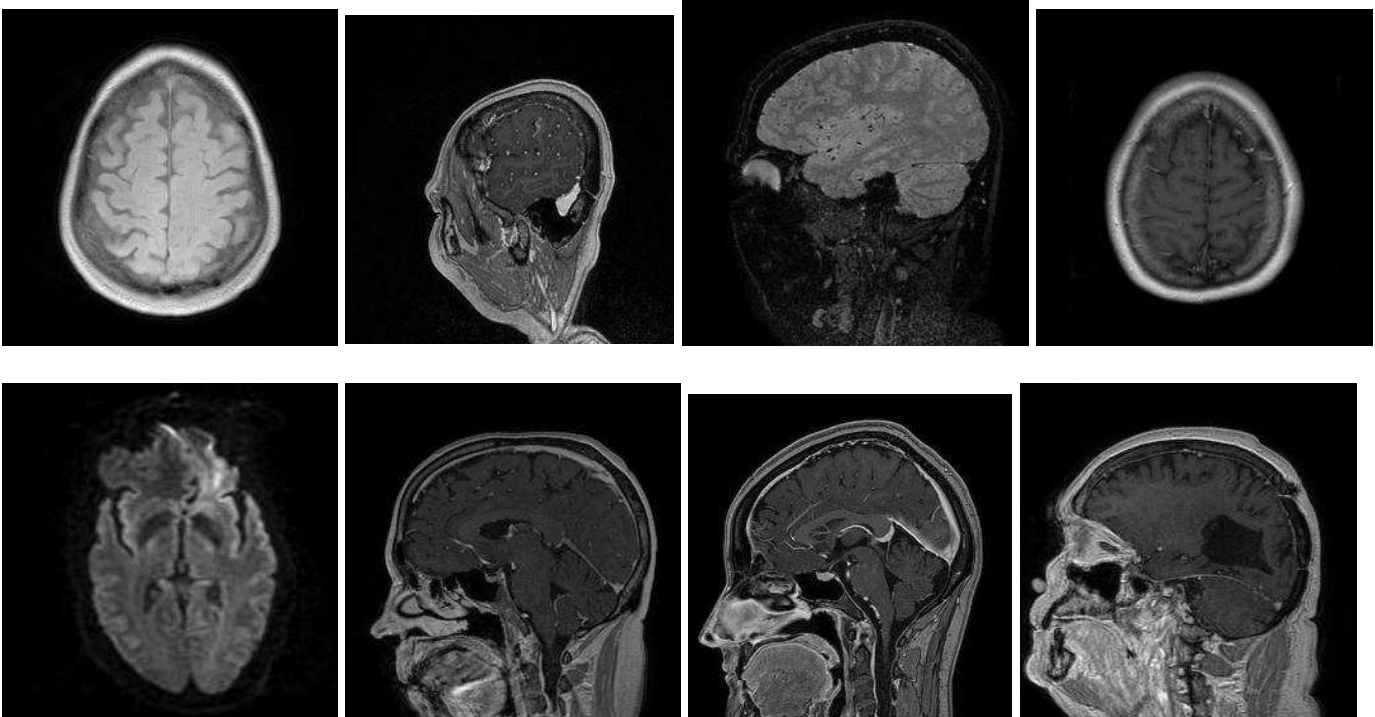
### Topic 75:

- Brain MR imaging, NOS. 2. [Terms not specific for a particular disease or process.]

- terms:

axial,images,seen,were,obtained,brain,identified,flair,sagittal,made,technique,examination,exam,signal,th  
rough,visualized,previous,evidence,ventricular,system,mri,impression,increased,sinuses,findings,reason,  
unremarkable,lesions,grossly,intensity,abnormal,masses,definite,spgr,weighted,clear,after,paranasal,coll  
ections,intracranial,diffusion,coronal,enhancing,however,comparison,changes,again,extra-  
axial,enhancement,intra

- images:



### Topic 76:

- DEXA. 3.

- terms:

score,area,bone,mass,average,were,standard,deviations,was,age,used,peak,matched,values,obtained,nor  
mal,made,following,comparisons,comments,vertebrae,population,neck,l1-  
l4,instrument,femoral,controls,bmd(g/cm2,scan,distal,"femur,wards","femur,total","femur,trochanteric",  
1/3,vertebrae(lateral,middle,radius(junction,l2-l4,qdr-  
4500,"femur,intertrochanteric",0.5,0.6,0.3,patient,0.4,0.2,0.7,0.1,mg/cc,control

- images:



NO IMAGE AVAILABLE

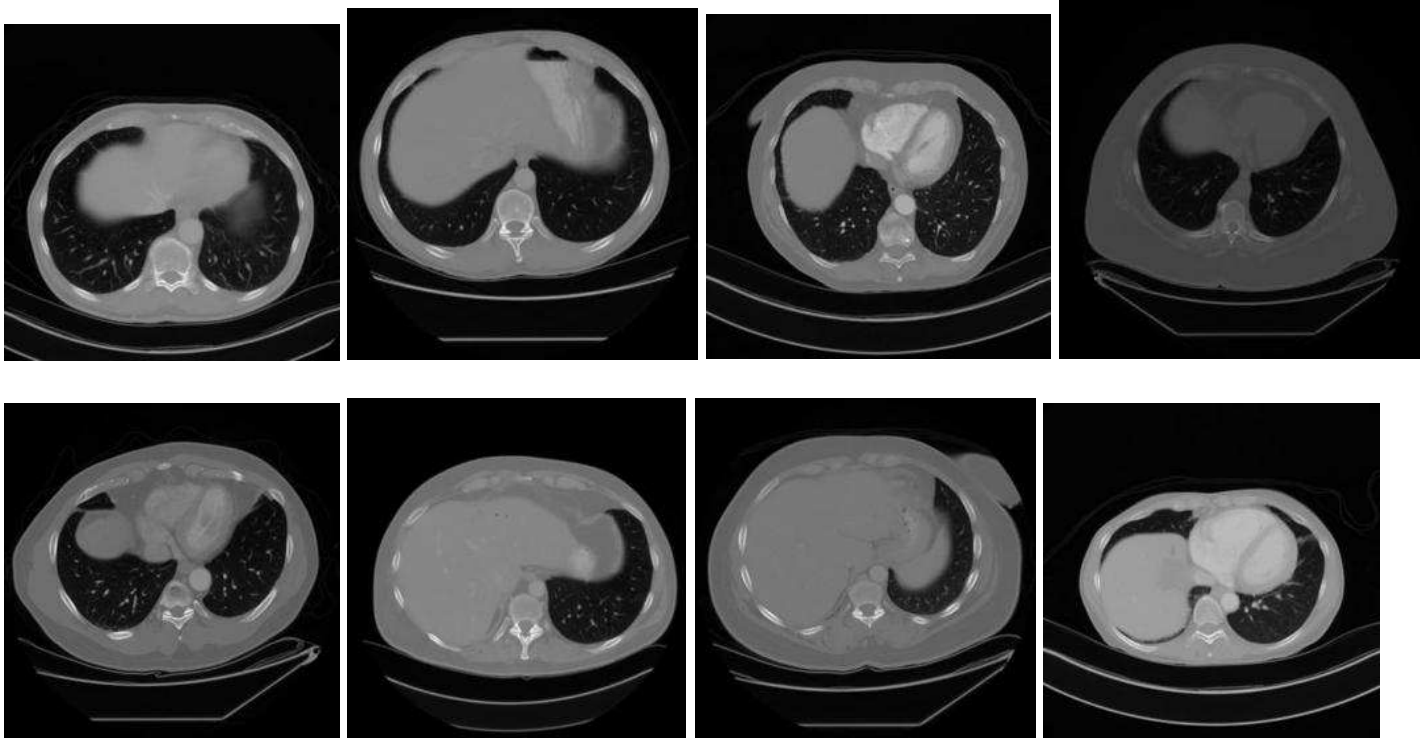
### Topic 77:

- Lymadenopathy. 3.

- terms:

compatible,adenopathy,series,unchanged,image,evidence,images,e.g,pelvis,lung,since,abdomen,vascular,minimal,foci,bulky,mass,calcification,bone,chest,contrast,liver,effusion,pleural,obtained,gross,following,without,splenomegaly,axilla,hydronephrosis,metastasis,bilateral,pericardial,increasing,helical,multidetector,apparent,complication,hilum,due,spine,gallbladder,administration,mesenteric,fat,dfov,cc/s,appearing,delay

- images:



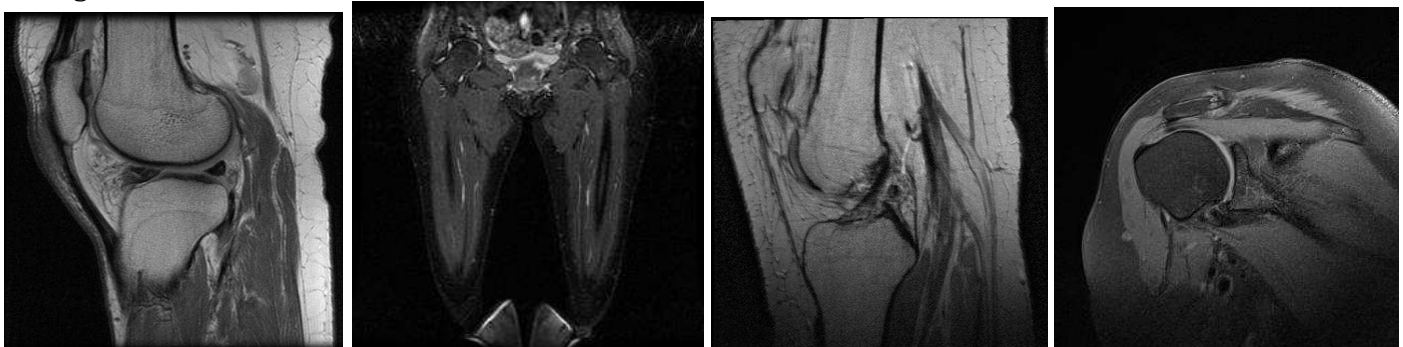
### Topic 78:

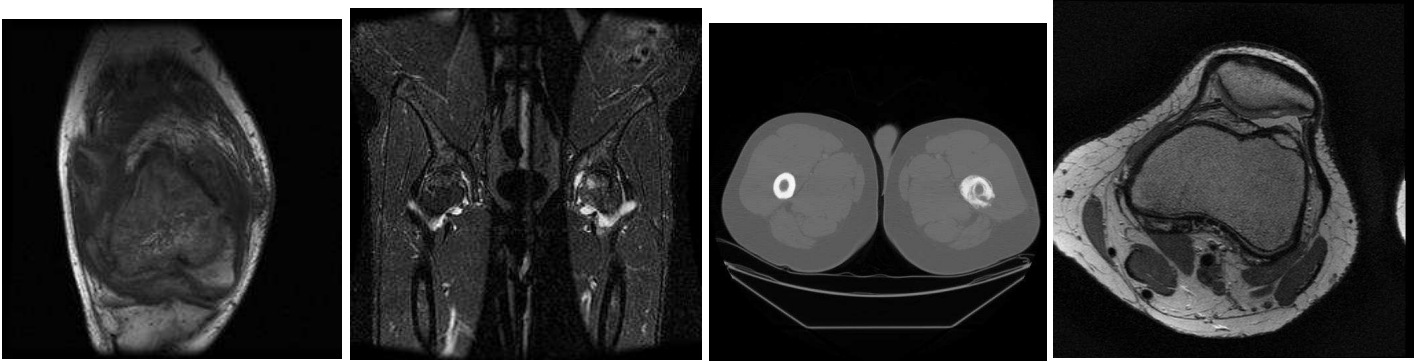
- Bone metastases. 3.

- terms:

bone,lesion,hip,knee,femoral,lytic,femur,proximal,head,sclerotic,joint,shoulder,hips,evidence,pelvis,distal,lesions,findings,humeral,lateral,fracture,medial,humerus,focal,impression,bony,prosthesis,history,iliac,pain,bilateral,blastic,avn,acetabulum,seen,marrow,sclerosis,view,both,osteolytic,cortical,heads,area,cortex,effusion,replacement,tibial,involving,consistent,views

- images:





**Topic 79:**

- Uncertainty/equivocation. 3. (small, however, although, probably, cannot, likely, difficult, possibl\*, somewhat, excluded)
- terms:  
this,not,may,that,small,which,represent,but,however,could,area,seen,appears,probably,some,does,patient ,cannot,although,very,due,these,likely,would,was,represents,also,difficult,possibly,finding,lesion,present, possible,have,can,most,well,appear,any,somewhat,suggest,related,other,one,see,whether,further,exclude d,because,within
- images:

